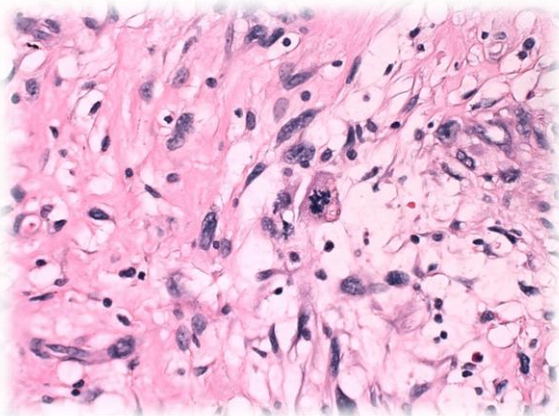
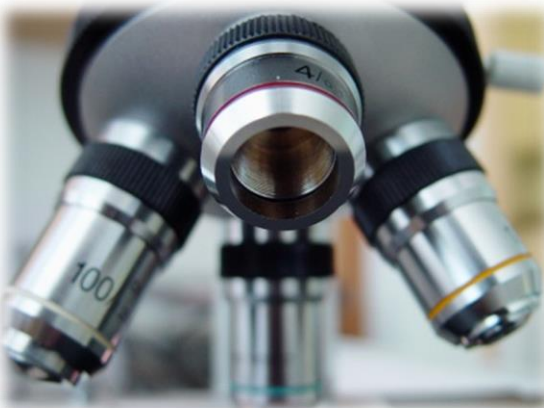
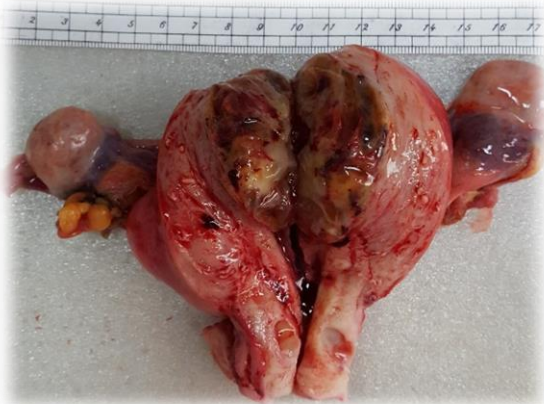prípád SD-IAP No.664

Karol Kajo

Ústav patológie OÚSA, Bratislava

karol.kajo@ousa.sk



Onkologický ústav sv. Alžbety, s.r.o.
812 50 Bratislava, Heydukova 10



anamnéza

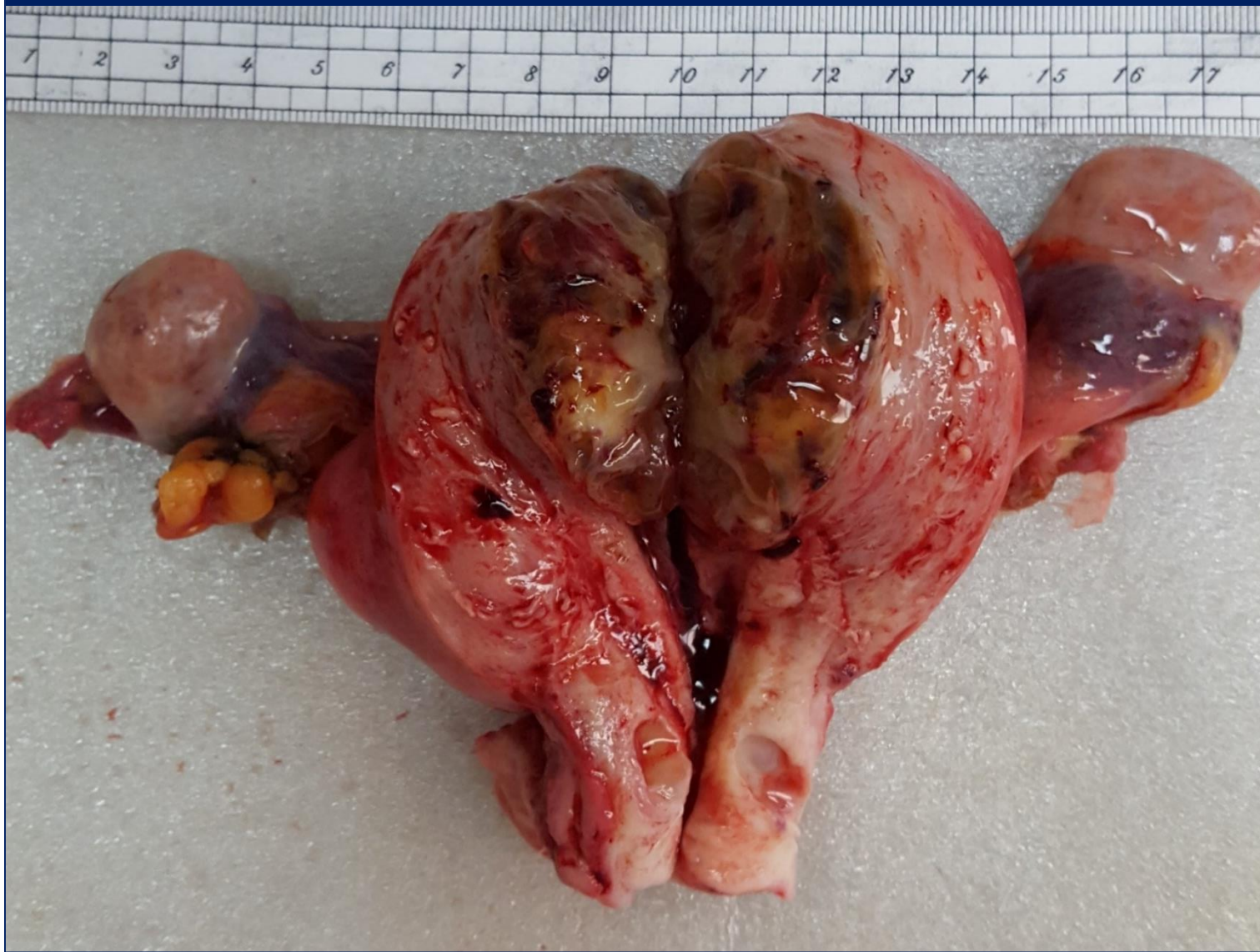GA: pôrody 4/4/1x gemini; Ab 0; UPT 0; menarche /menopausa 14/52; MC: bol pravidelný

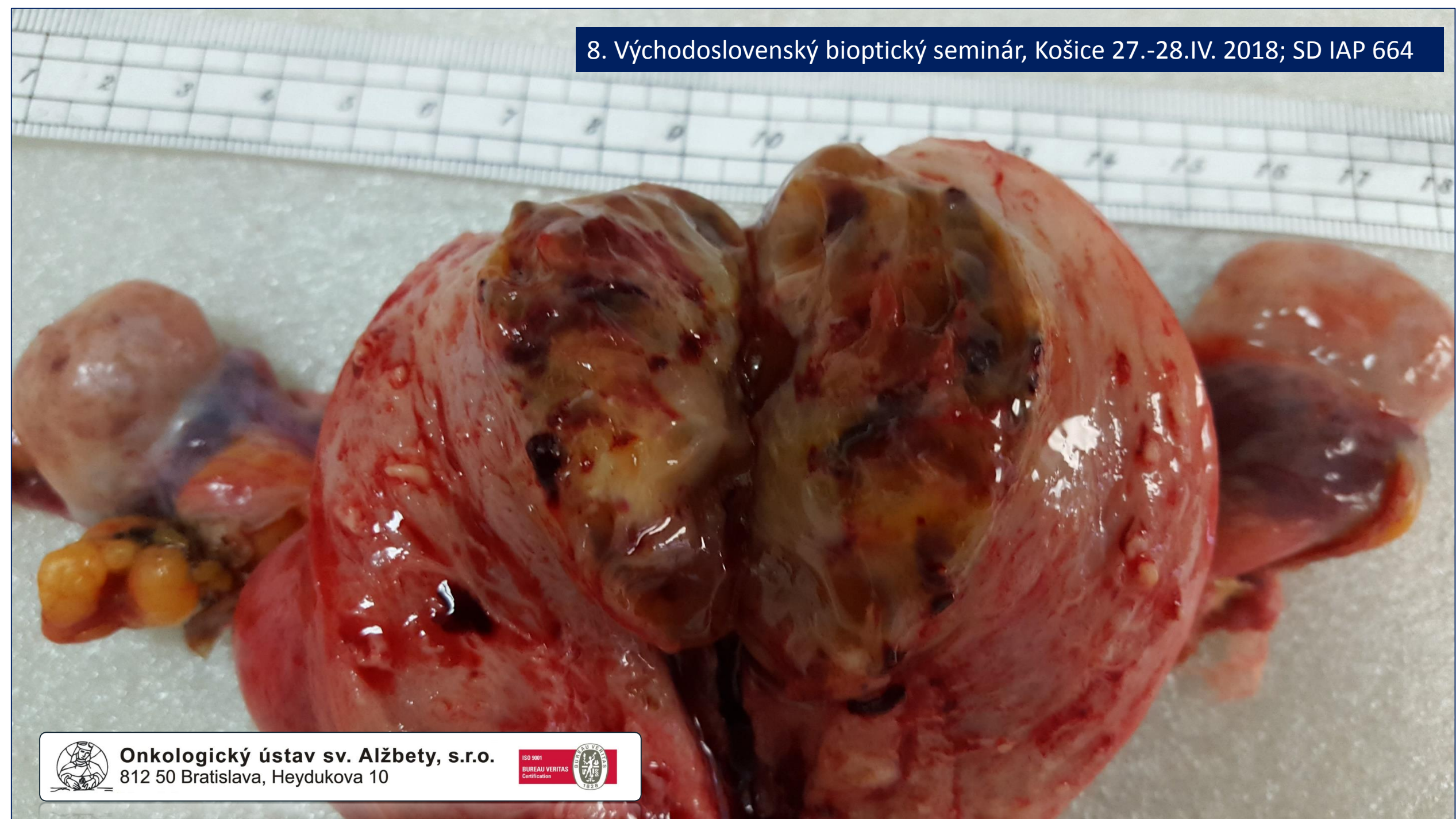- **66-r. žena** – za rok schudla 20kg
- od 10/2017 hrčka v ľavom prsníku (bolesti v ľavej axile)
- **12/2017 bolesti v podbrušku** – spádový gynekológ zistil **USG štrukturálne zmeny maternice, v.s. neo proces**
- 12.12.2017 – OÚSA – uterus grav. m.III; TVS-uterus AVF, AP 85x57, myometrium nehomogénne, **vo funde tumor 50x47mm, ostro ohraničený, s hyperechogénnymi zónami okolo anechogénnych dutiniek rôznej veľkosti – nekrotický myóm?** iné? Na zadnej stene subserózný uzol do 30mm, endometrium nie je diferencované, v oblasti prechodu istmu a cervixu je ložisko 14x6mm – polyp? Ovaria nie sú viditeľné, CD bez voľnej tekutiny
- 22.01.2018 operácia **HYE+AXE bilat.**; adheziolysis, lavage cavi abdomini



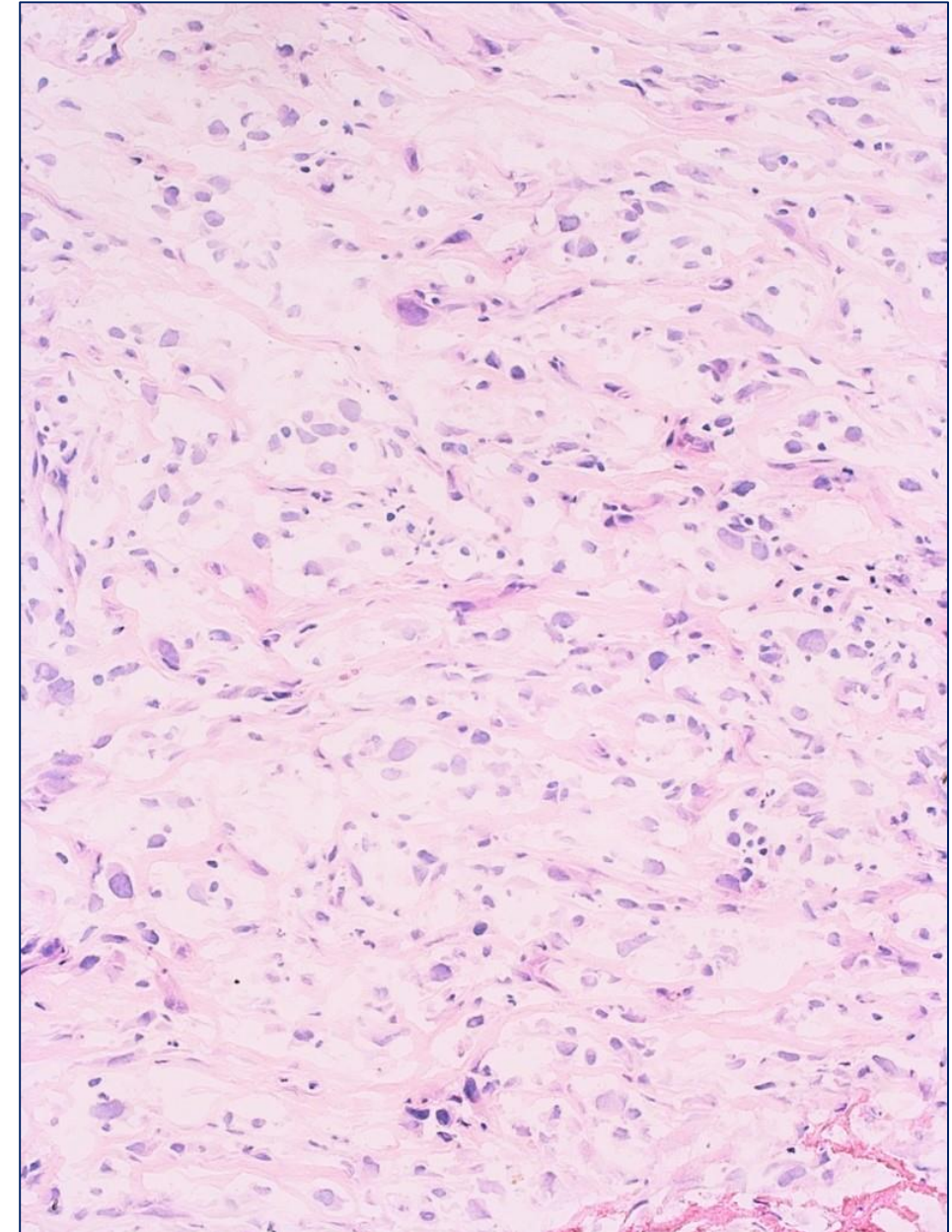
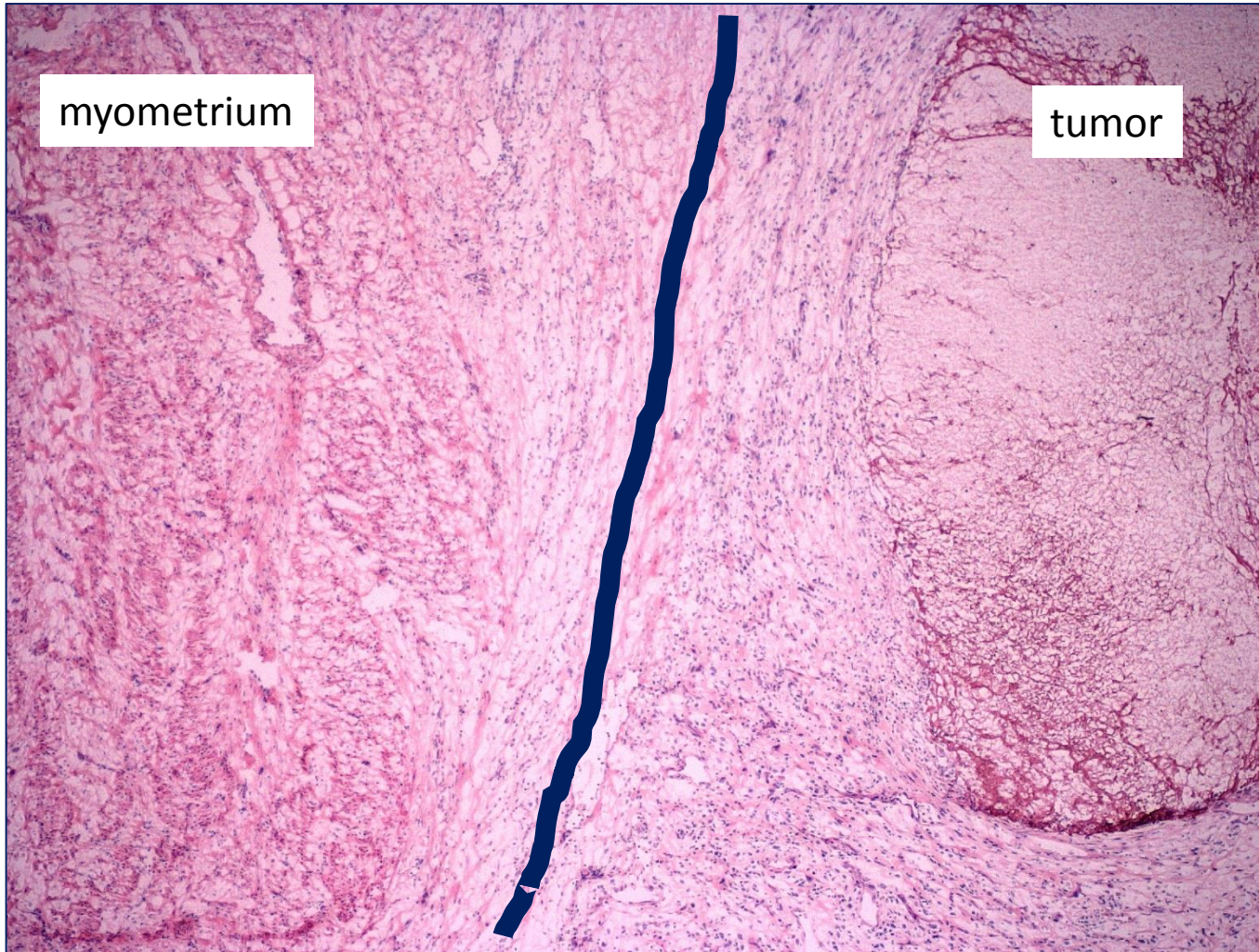
makroskopický nález

- polypoidne prominujúca nádorová masa vyplňajúca celú dutinu
- relatívne ohraničená voči myometriu
- veľkosť **50x45mm**
- na reze „kypiacá“, mramorovitá štruktúra, okrovo-belavej farby, hlienové hmoty
- zreteľné **regresívne zmeny** – nekrózy, krvácania, tvorba dutinových formácií

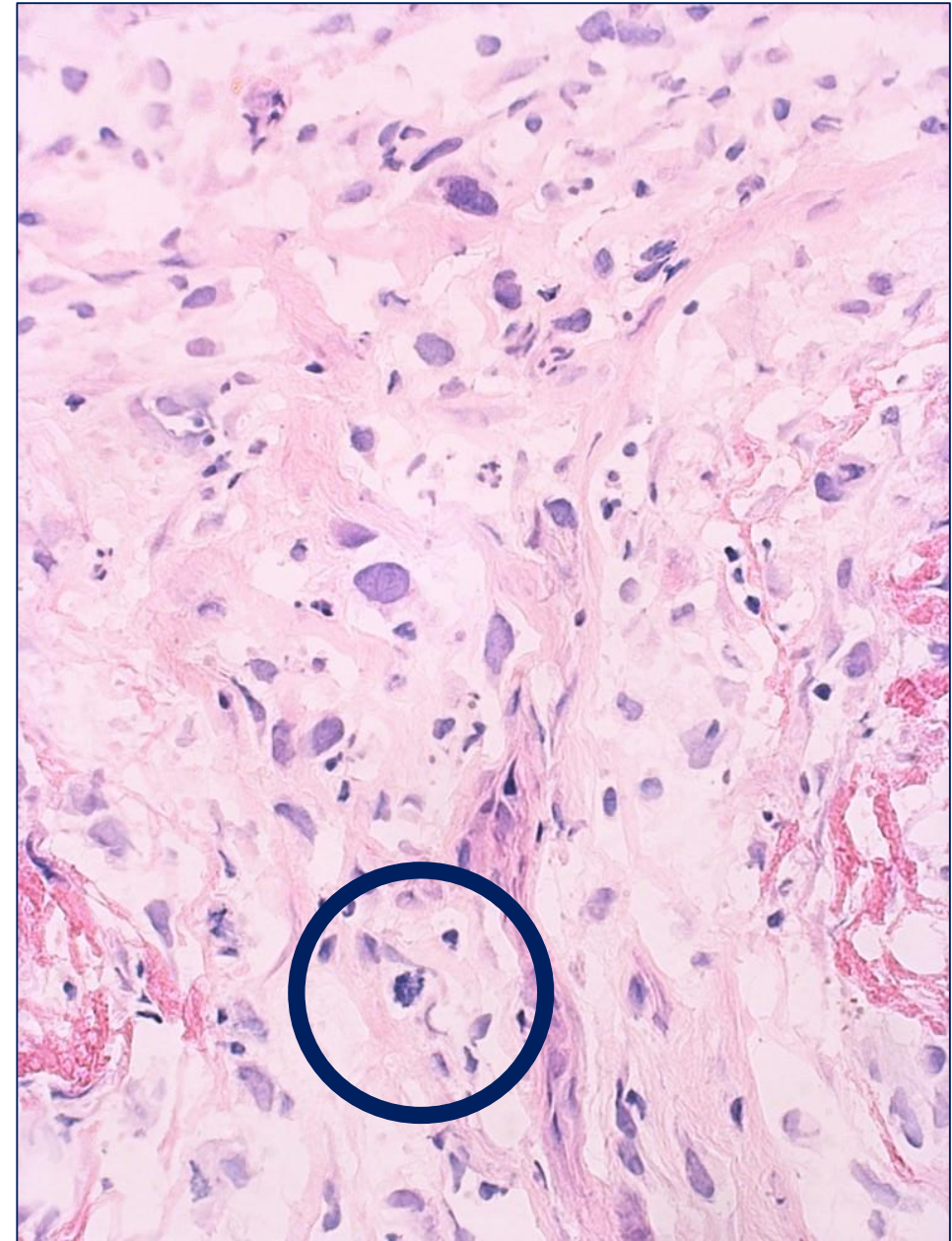
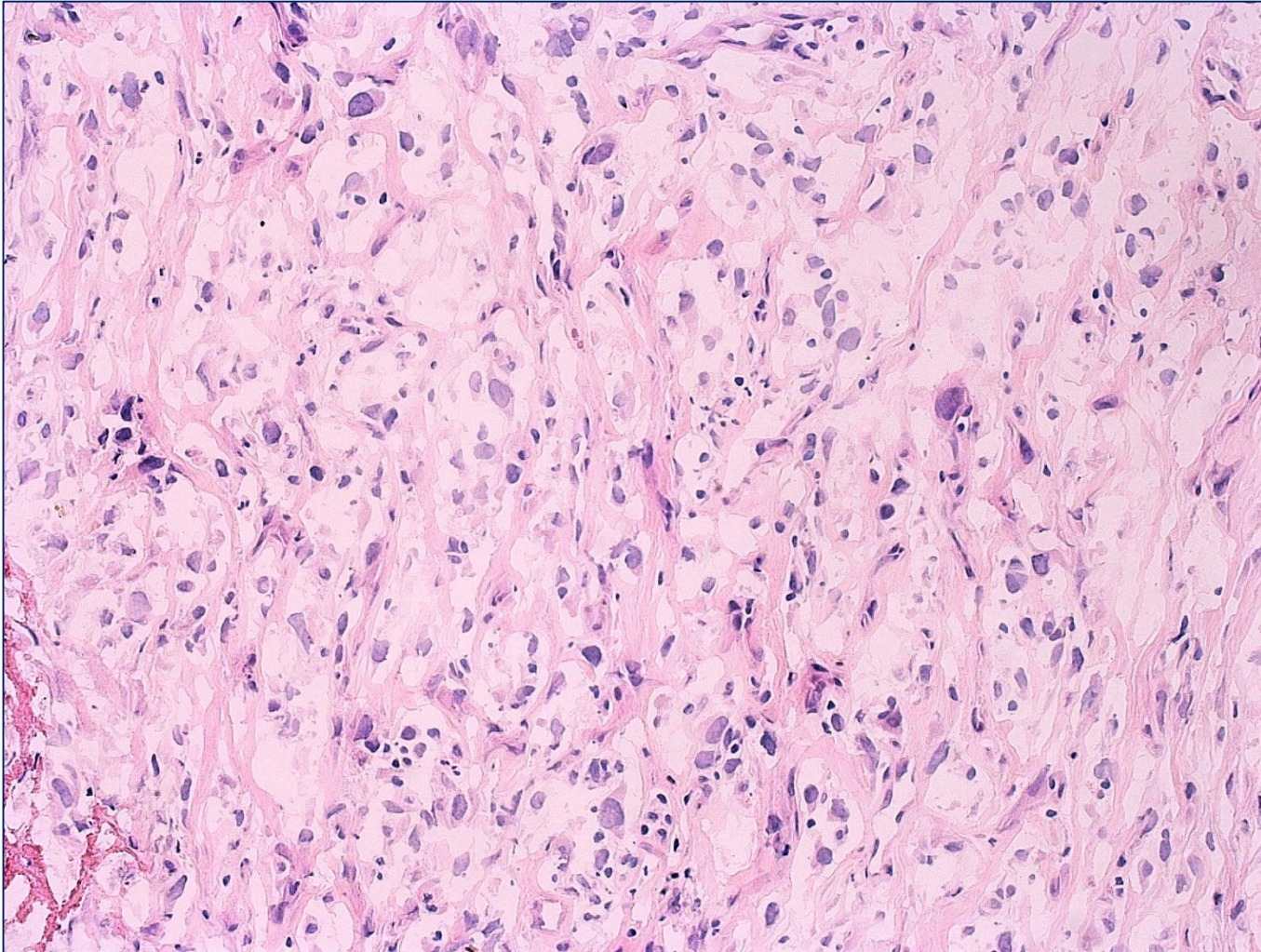




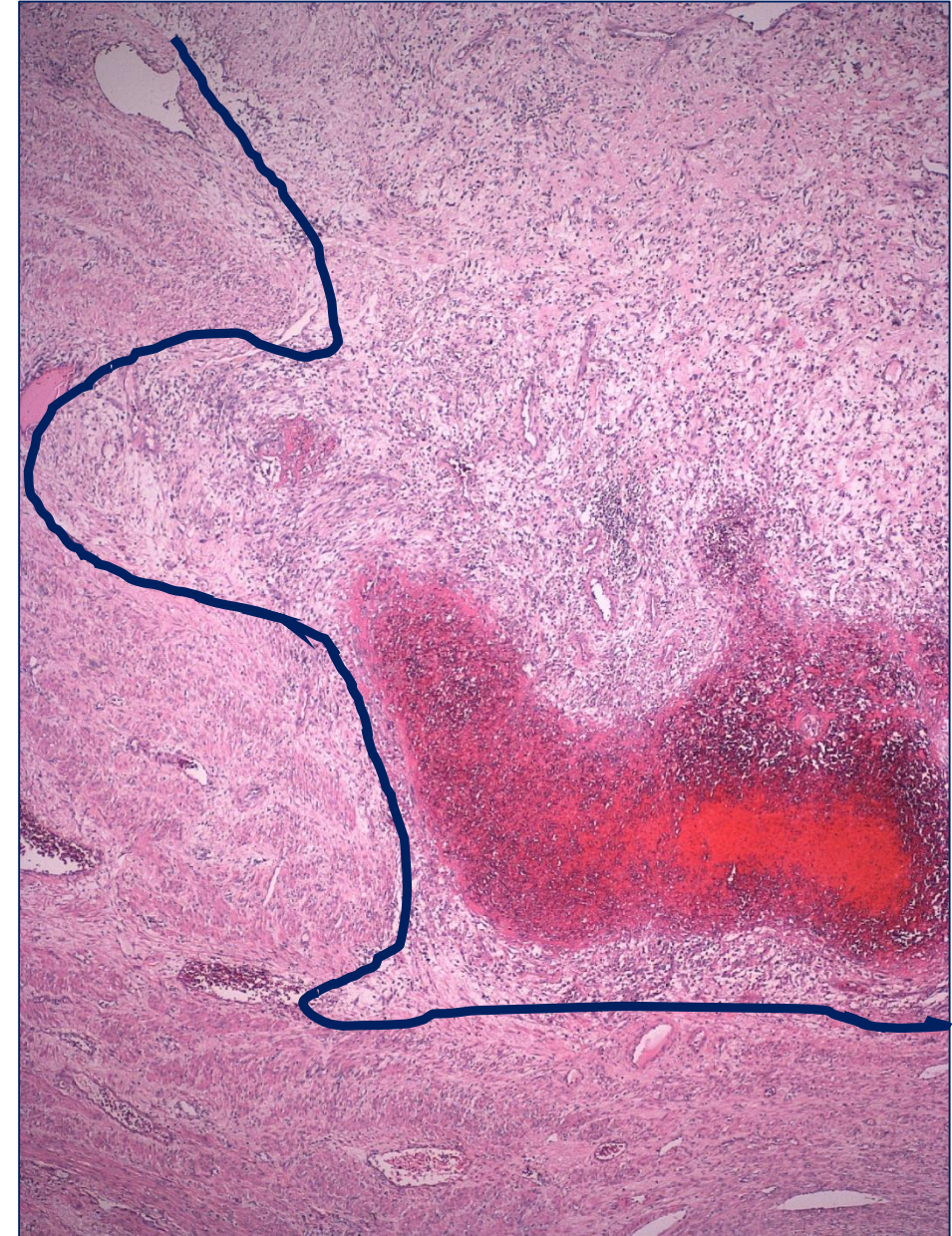
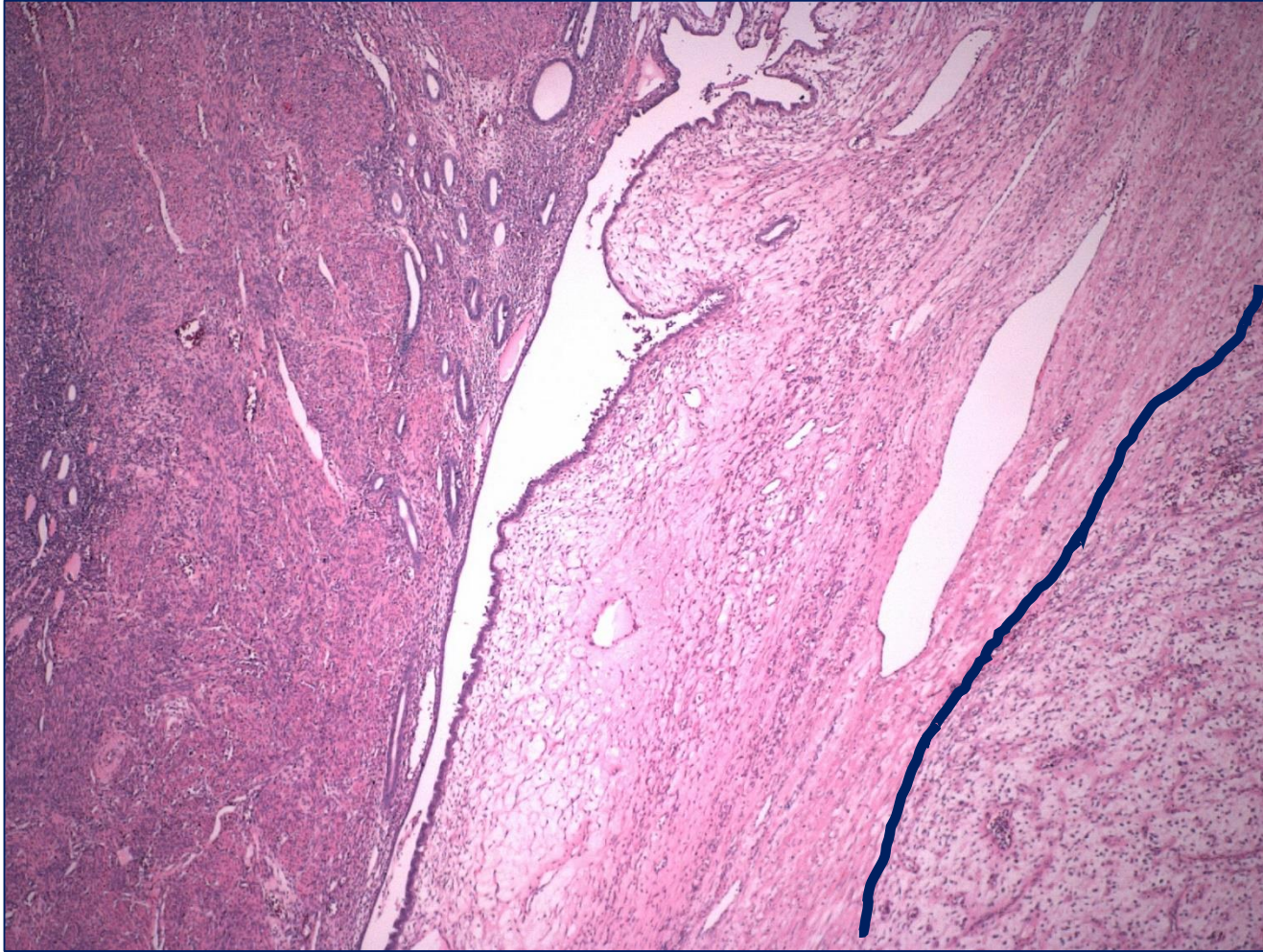
peroperačná biopsia



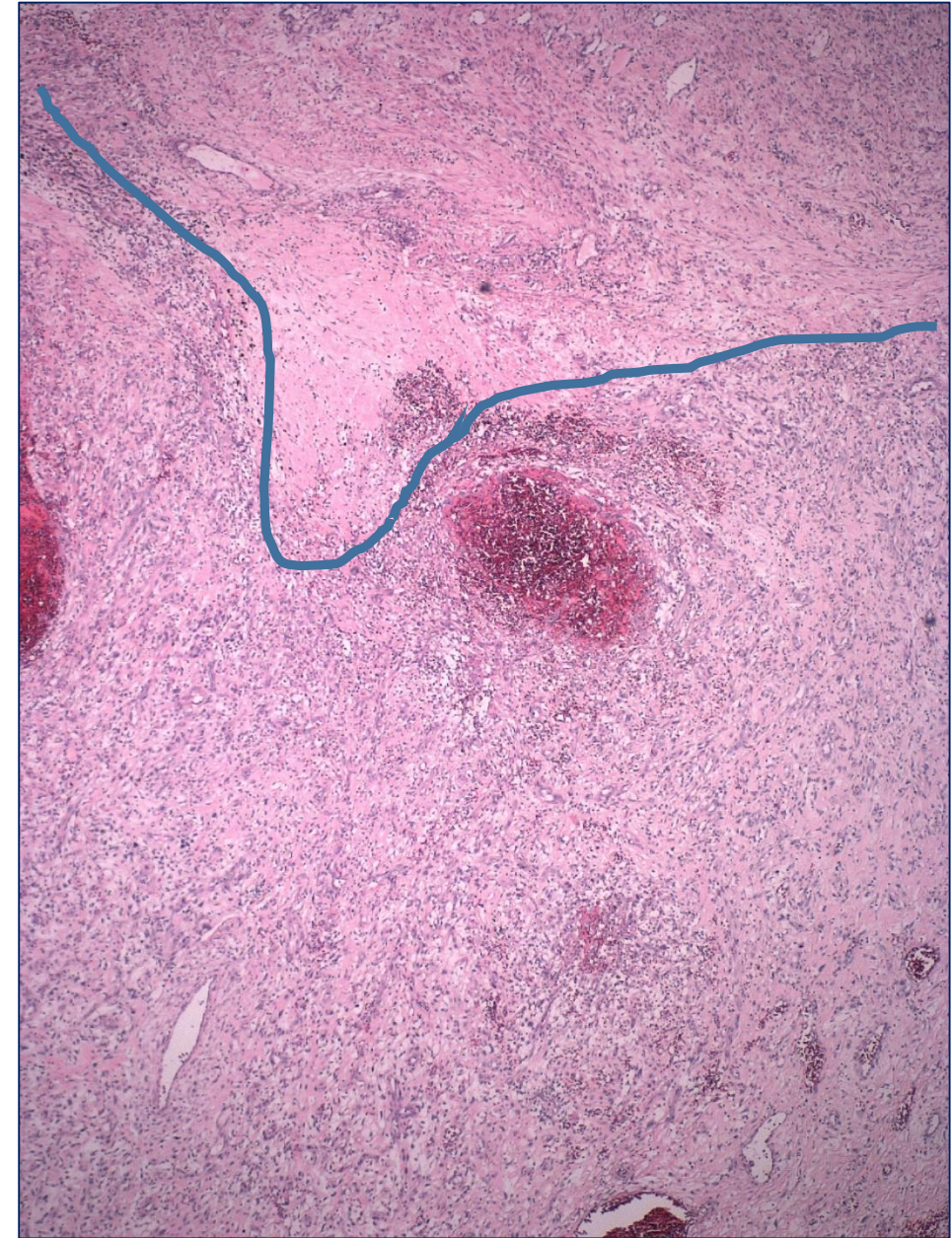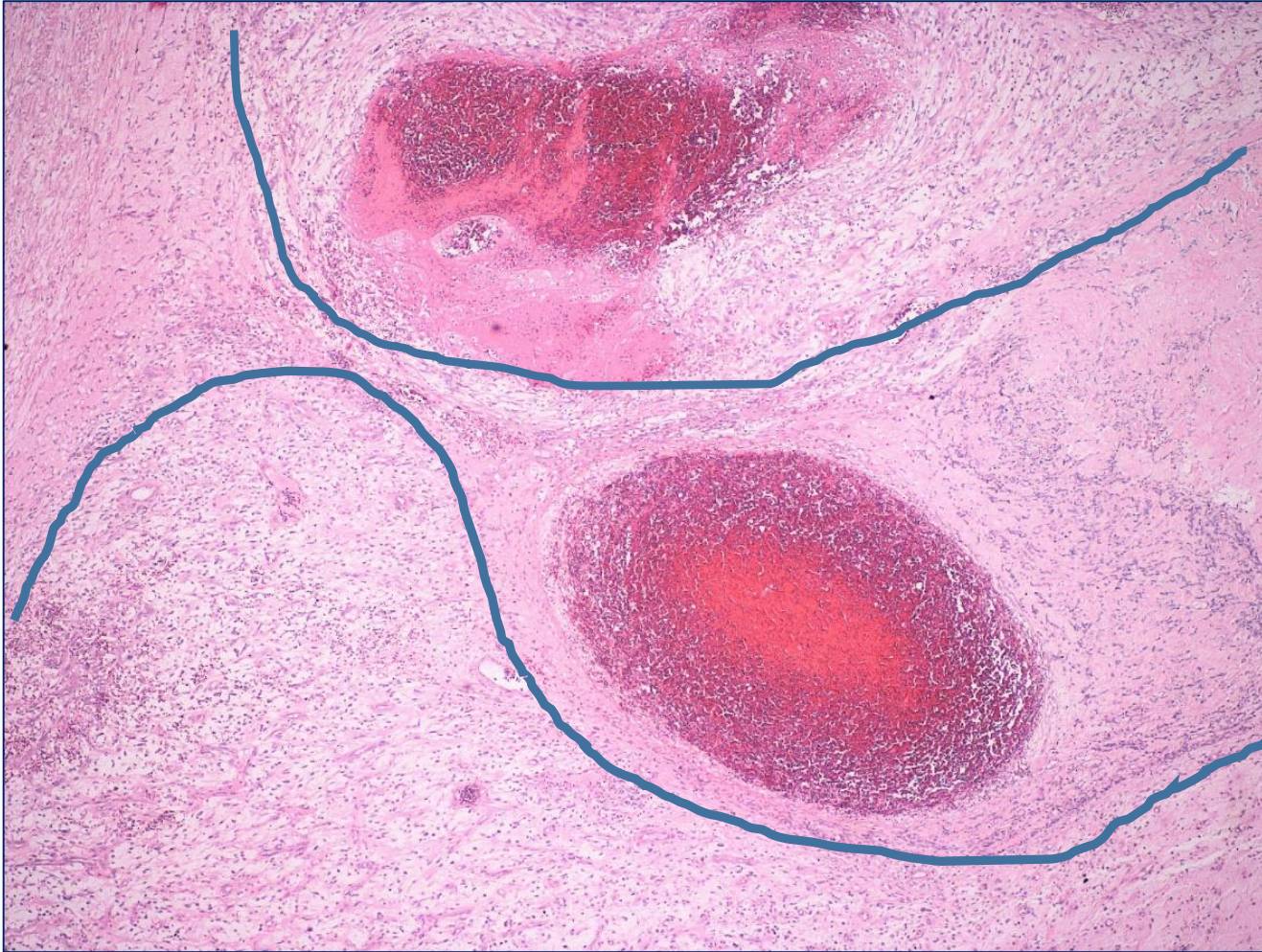
peroperačná biopsia



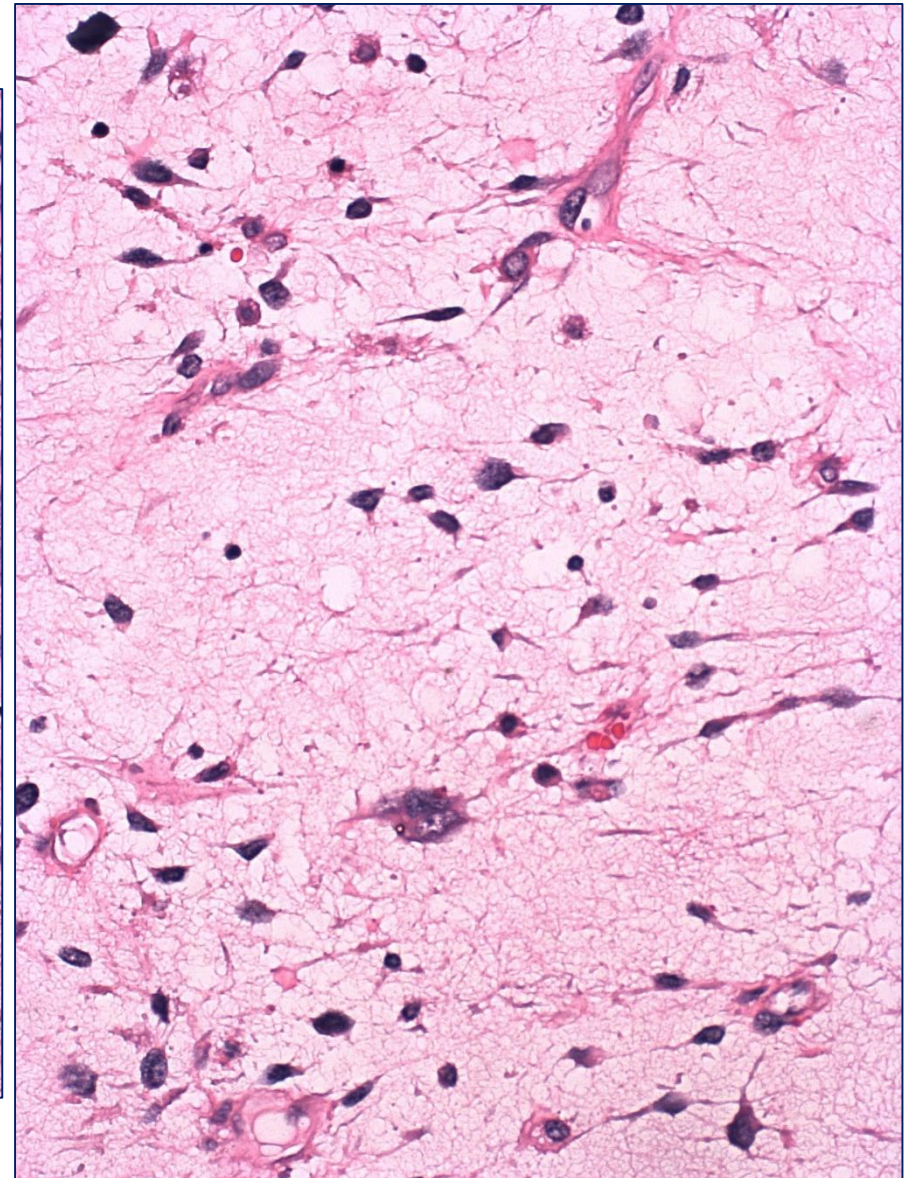
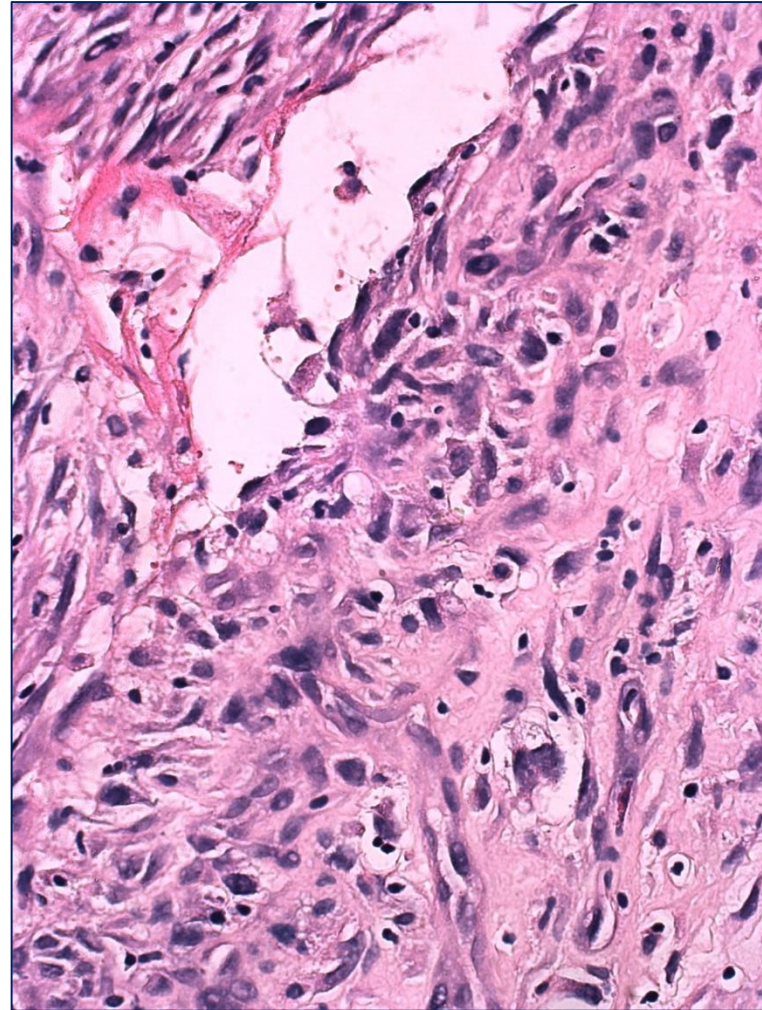
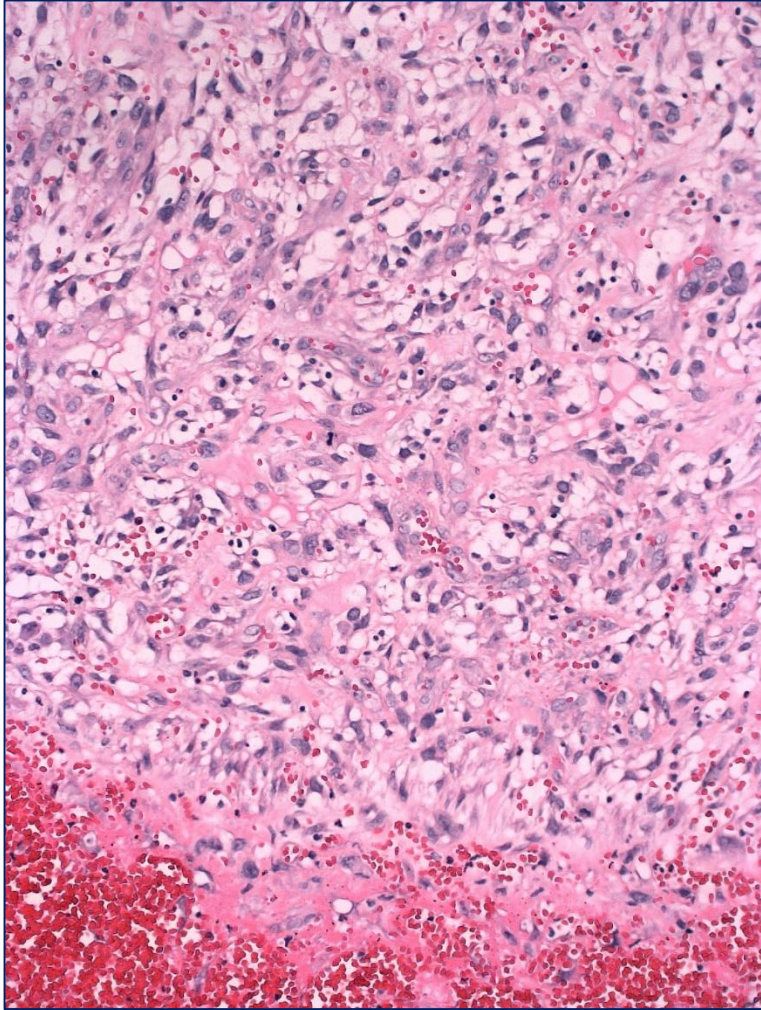
definitívna histológia – okraje nádoru



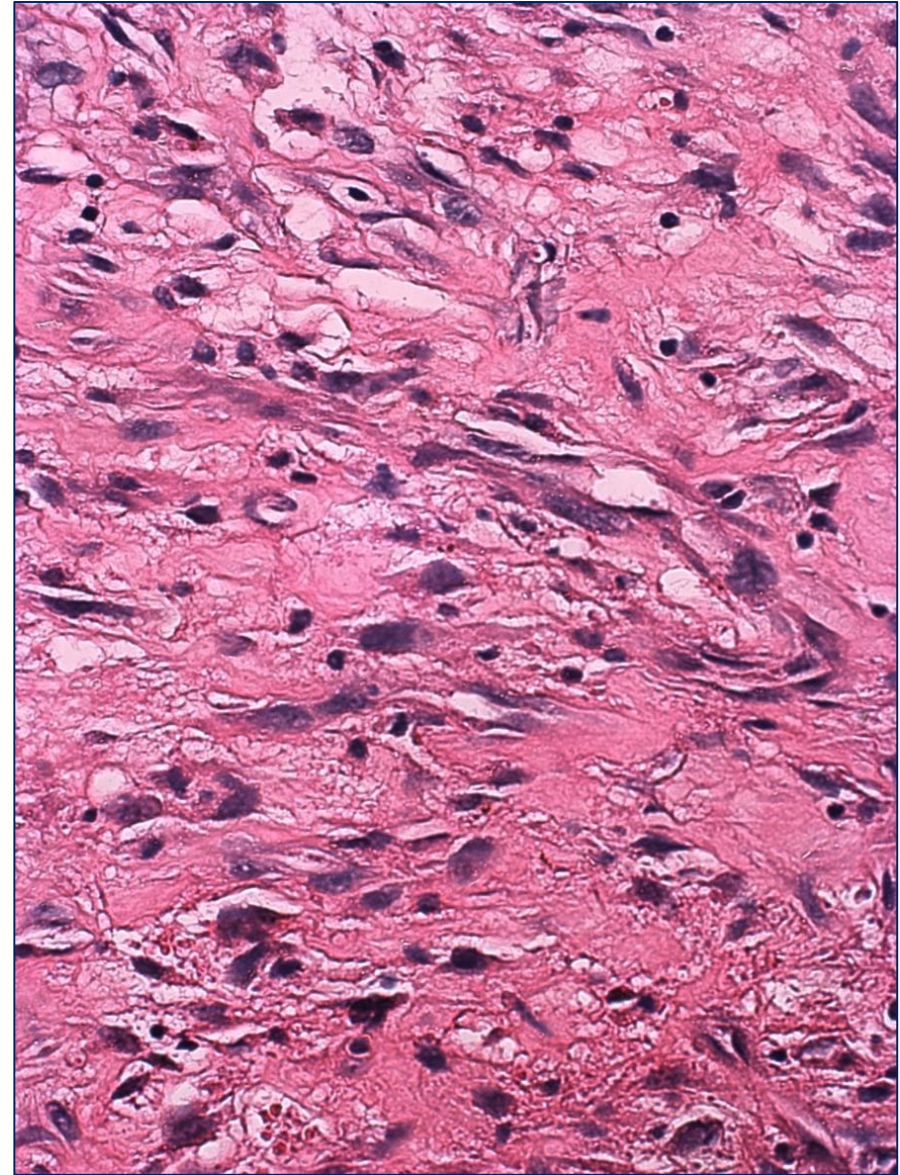
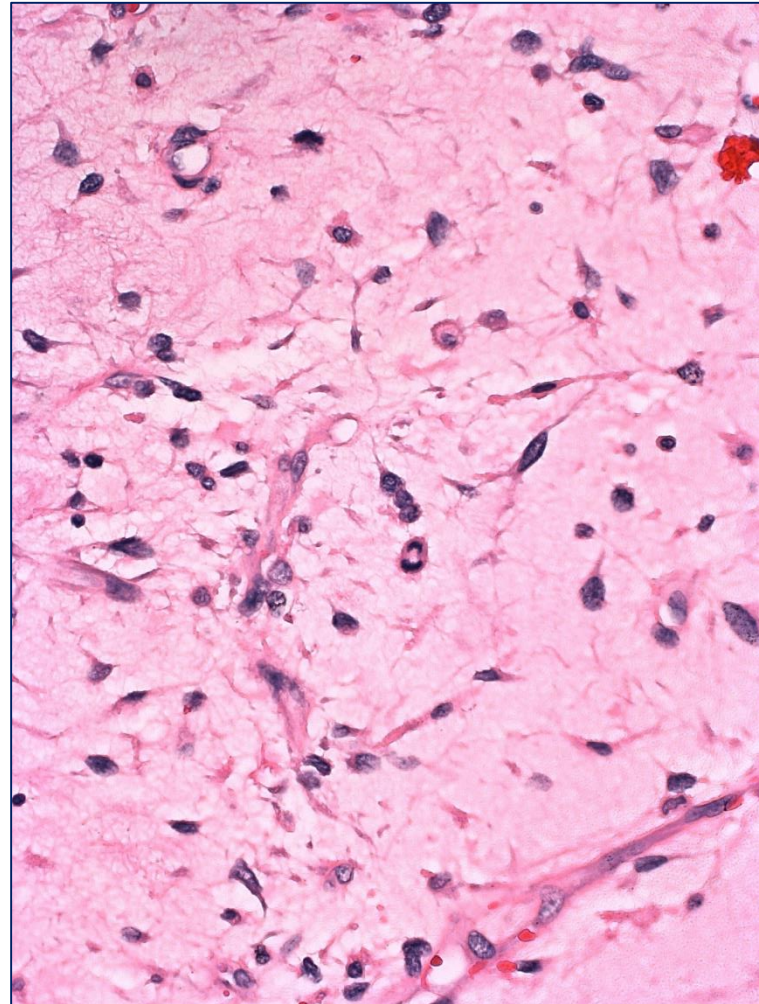
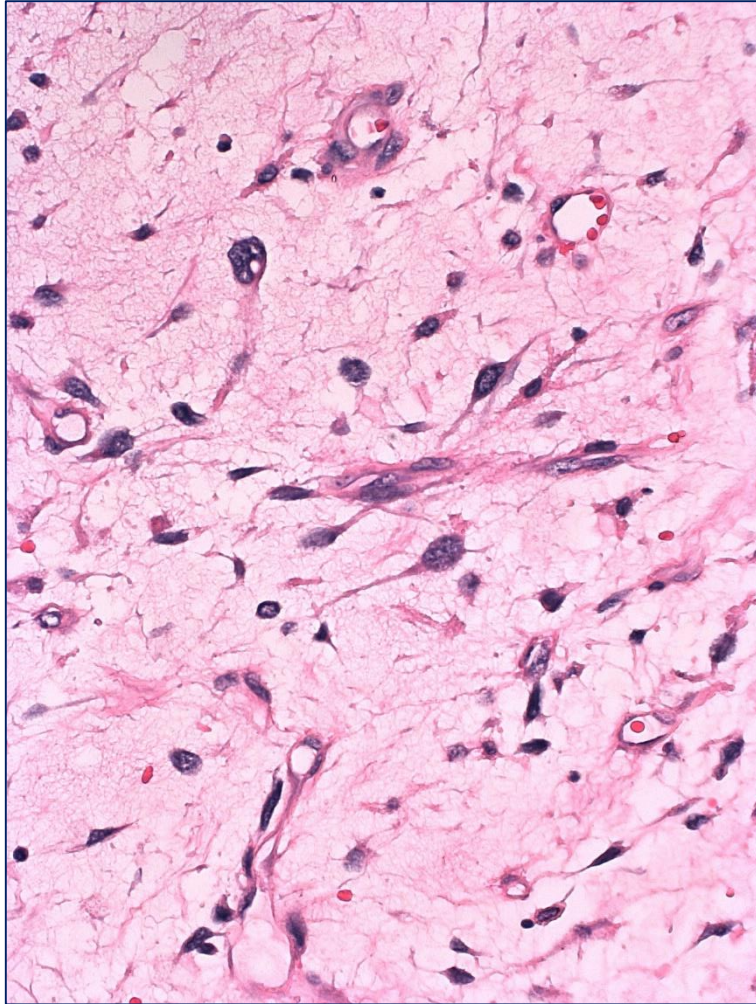
definitívna histológia – okraje nádoru



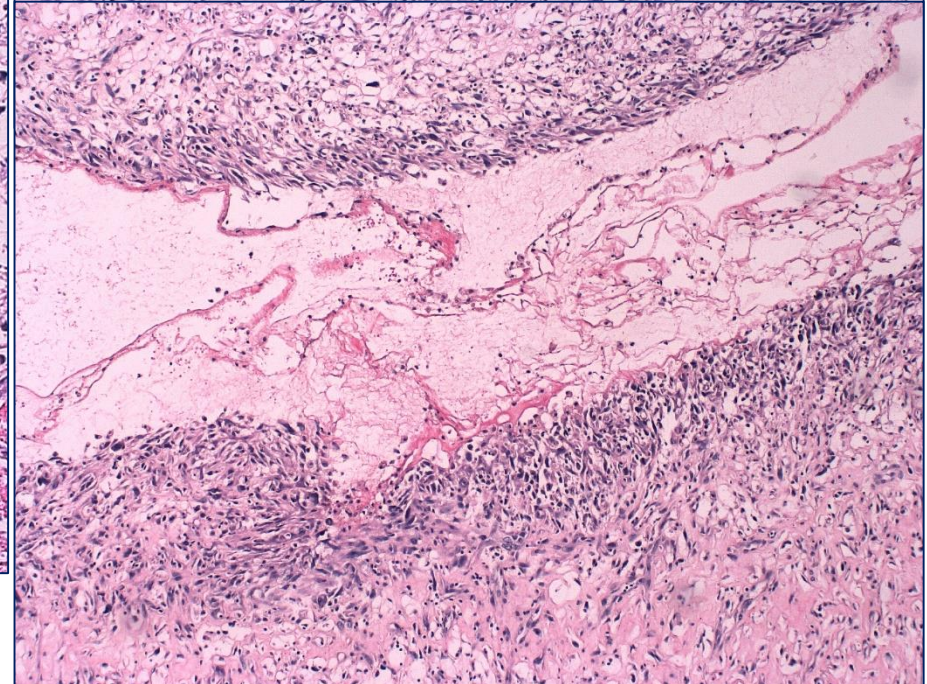
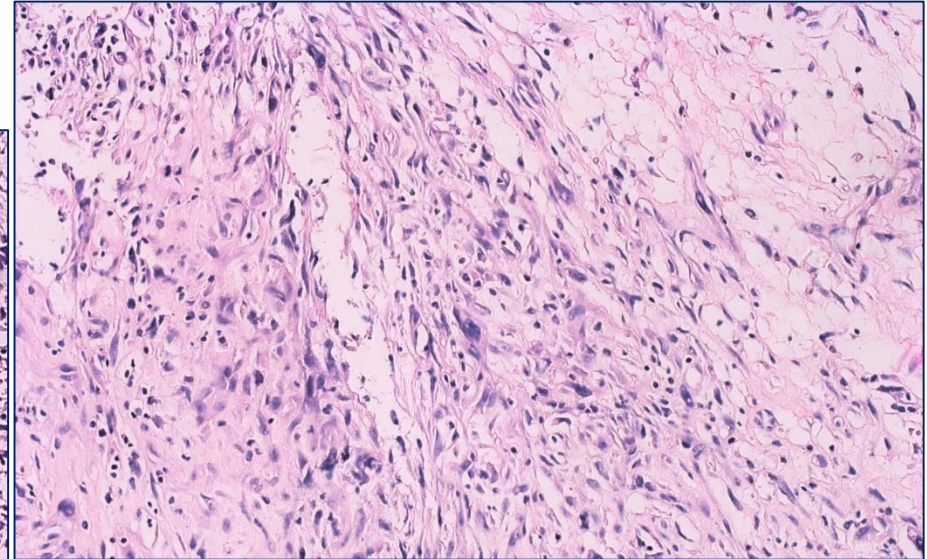
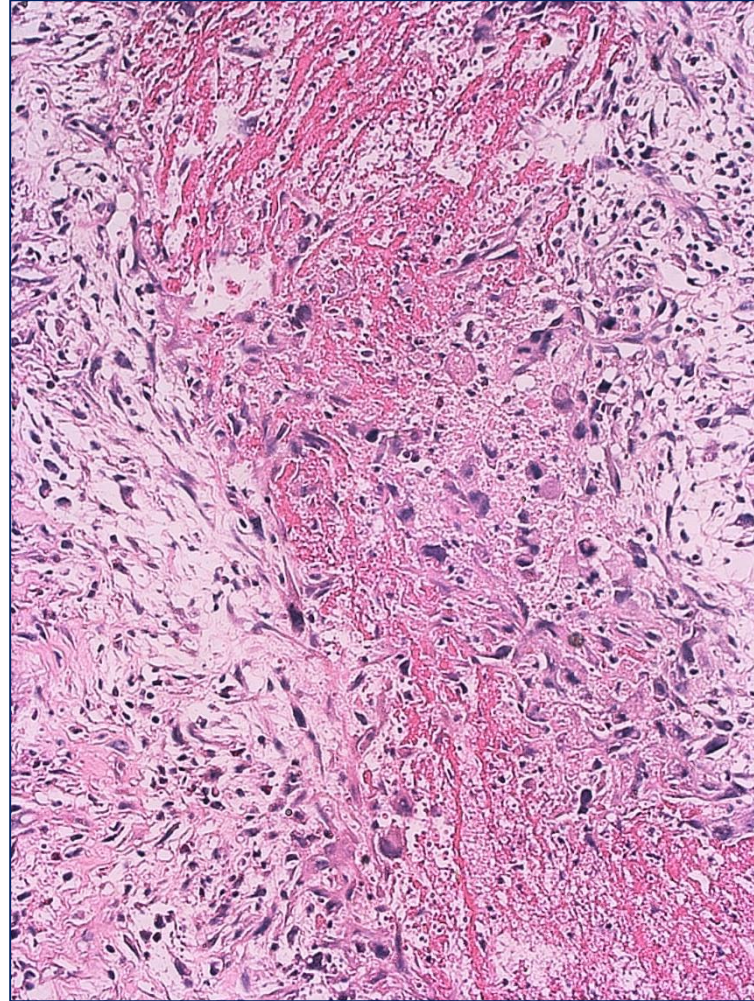
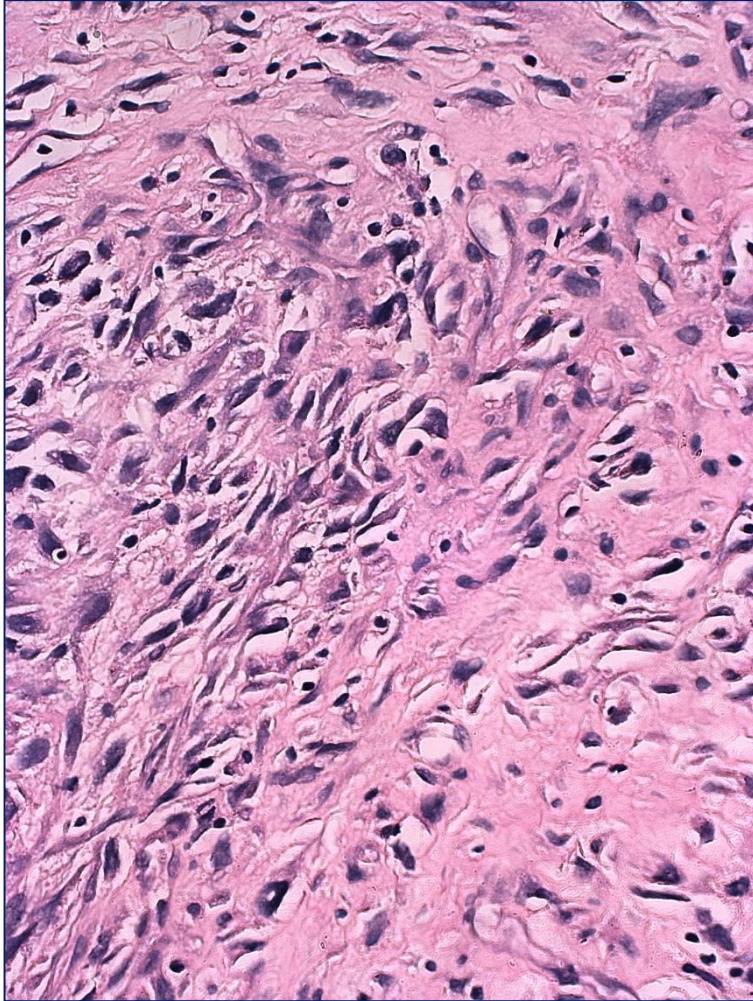
definitívna histológia – celularita



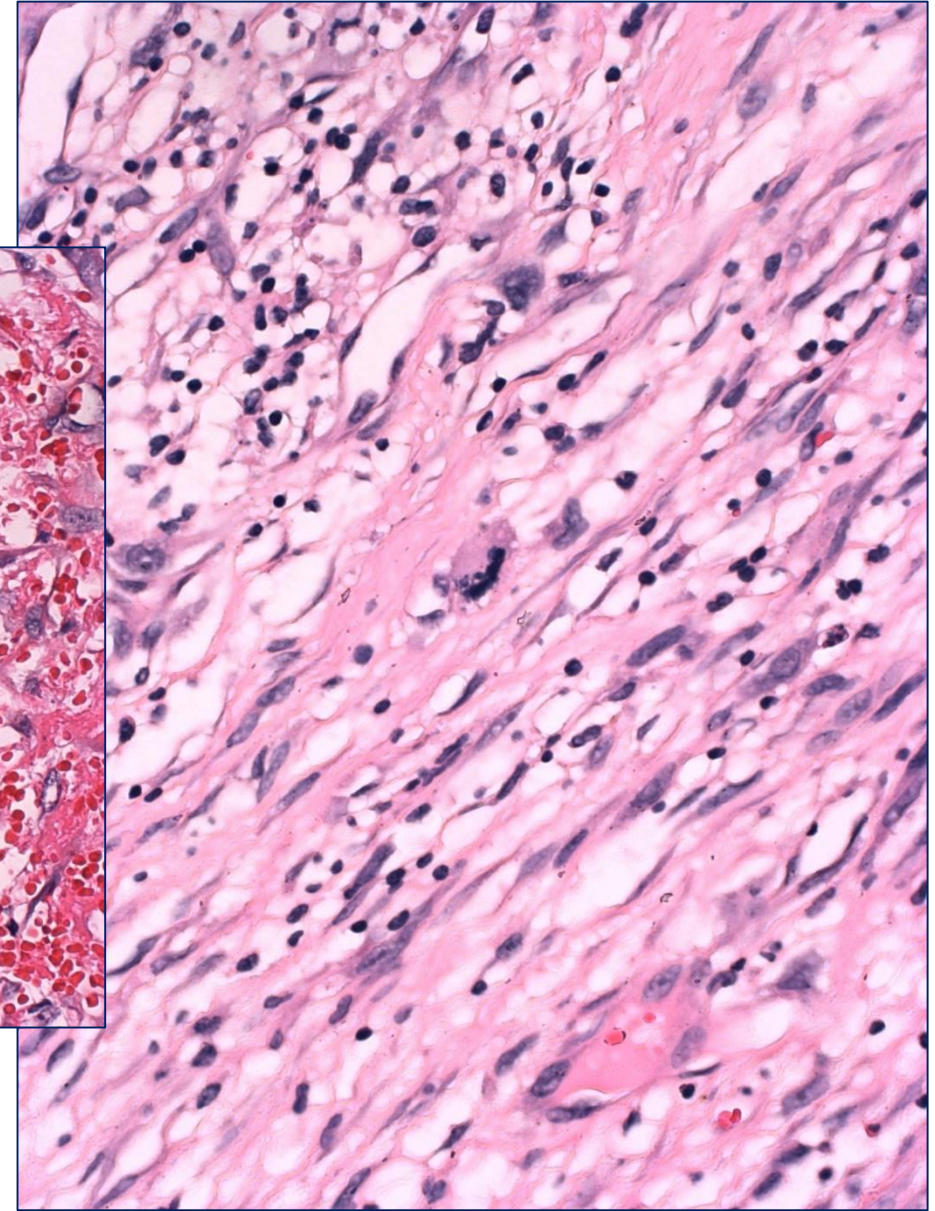
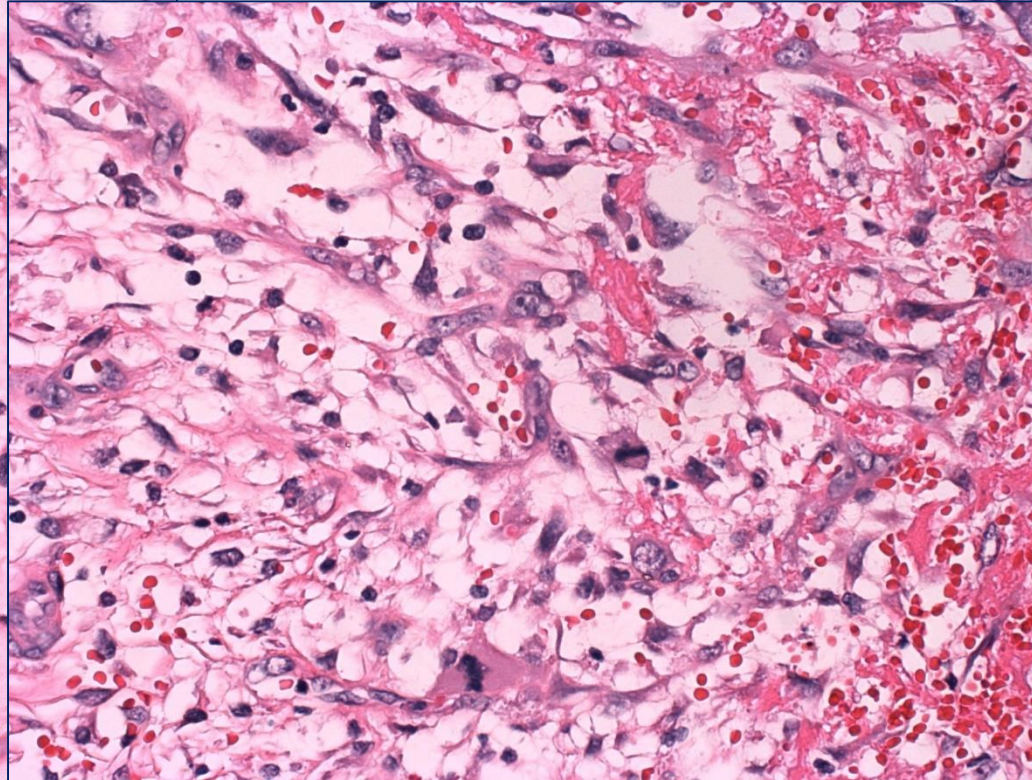
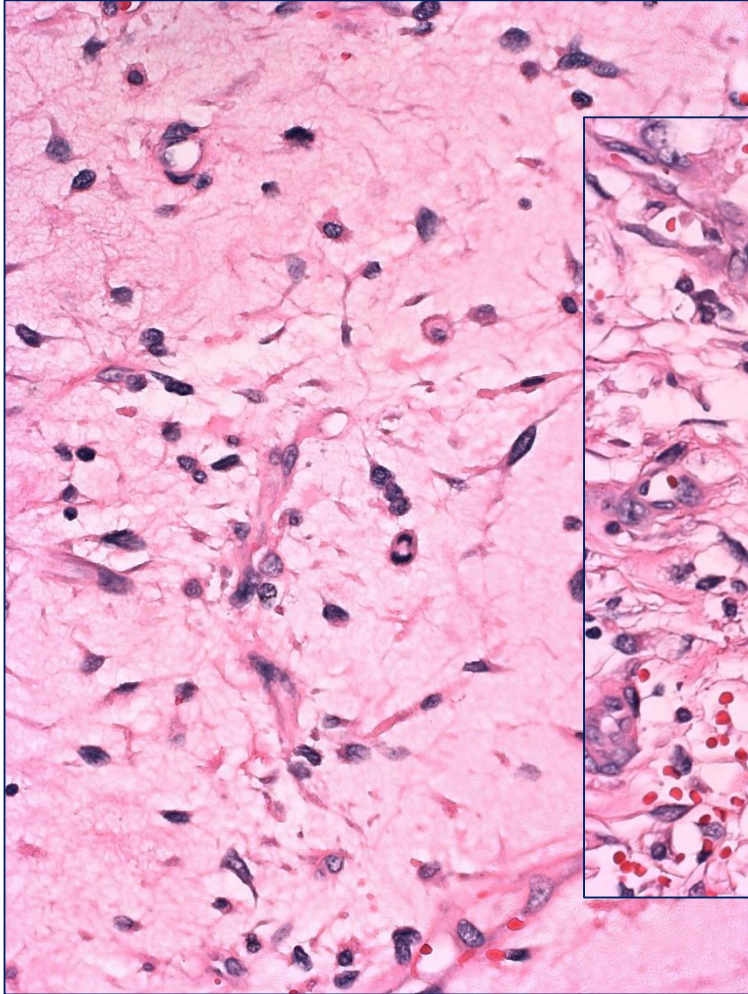
definitívna histológia – celularita



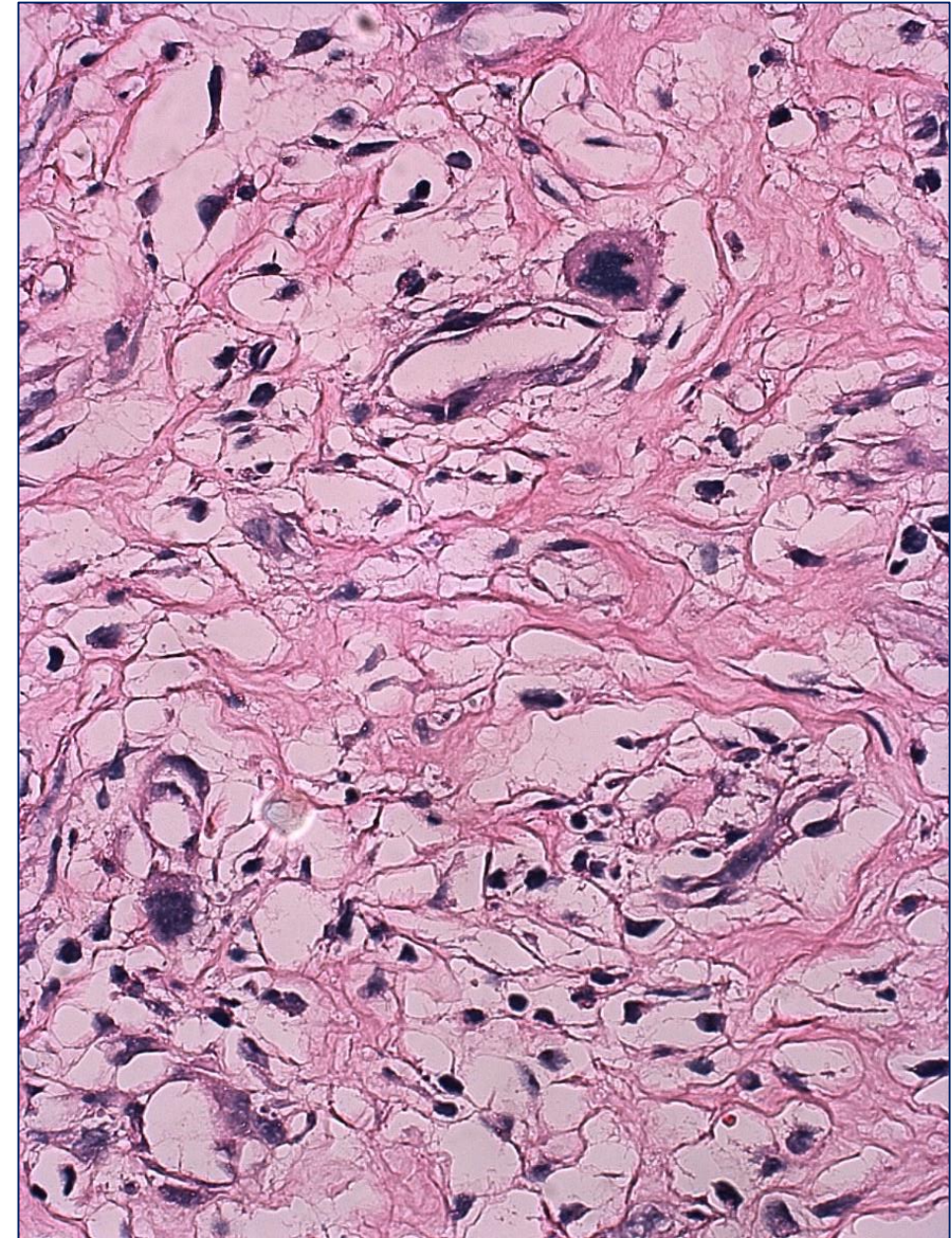
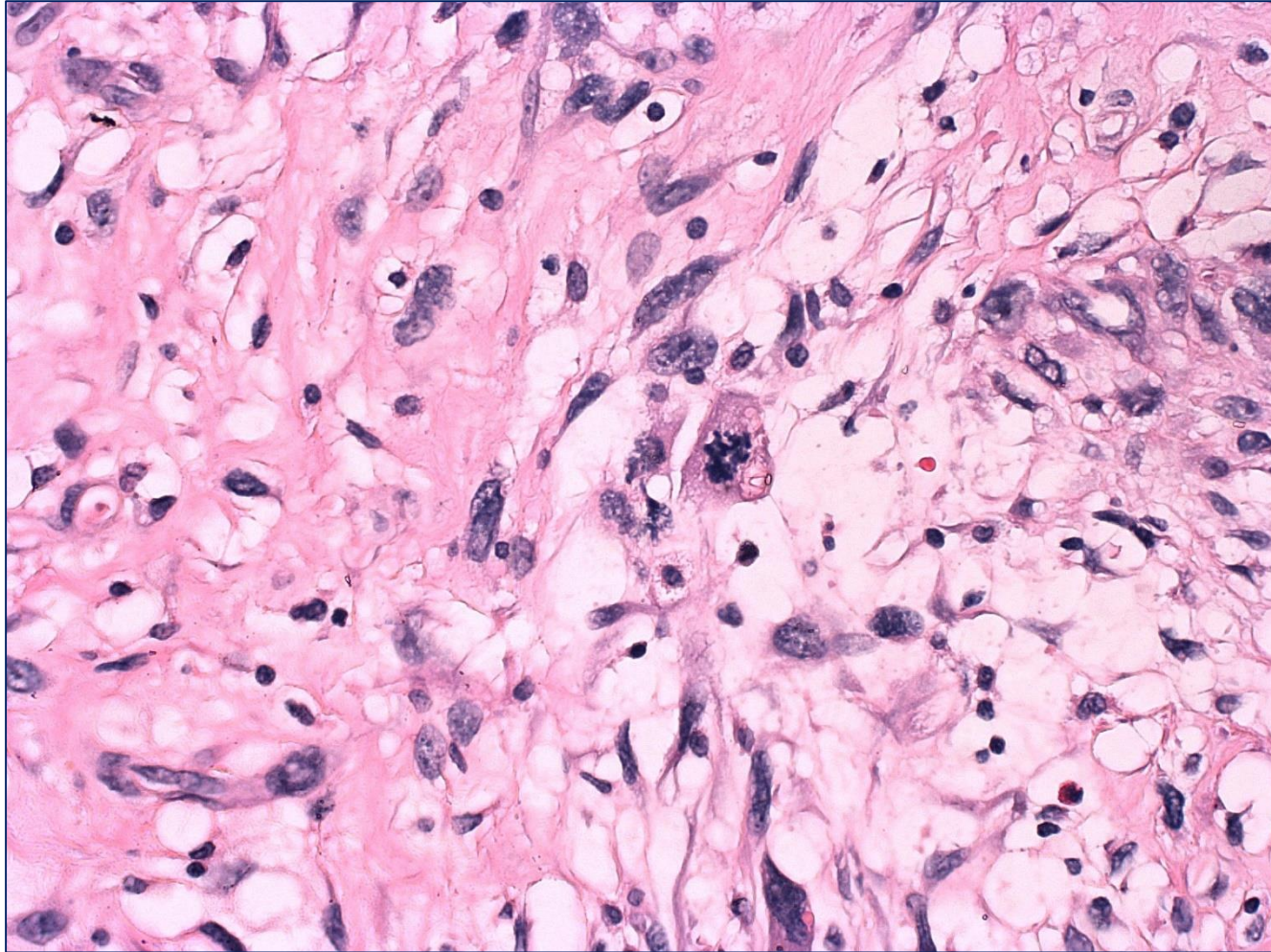
definitívna histológia – celularita



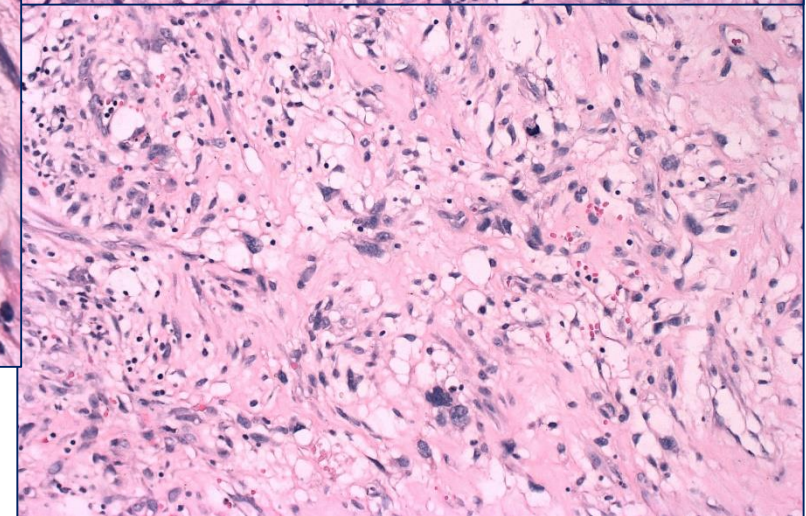
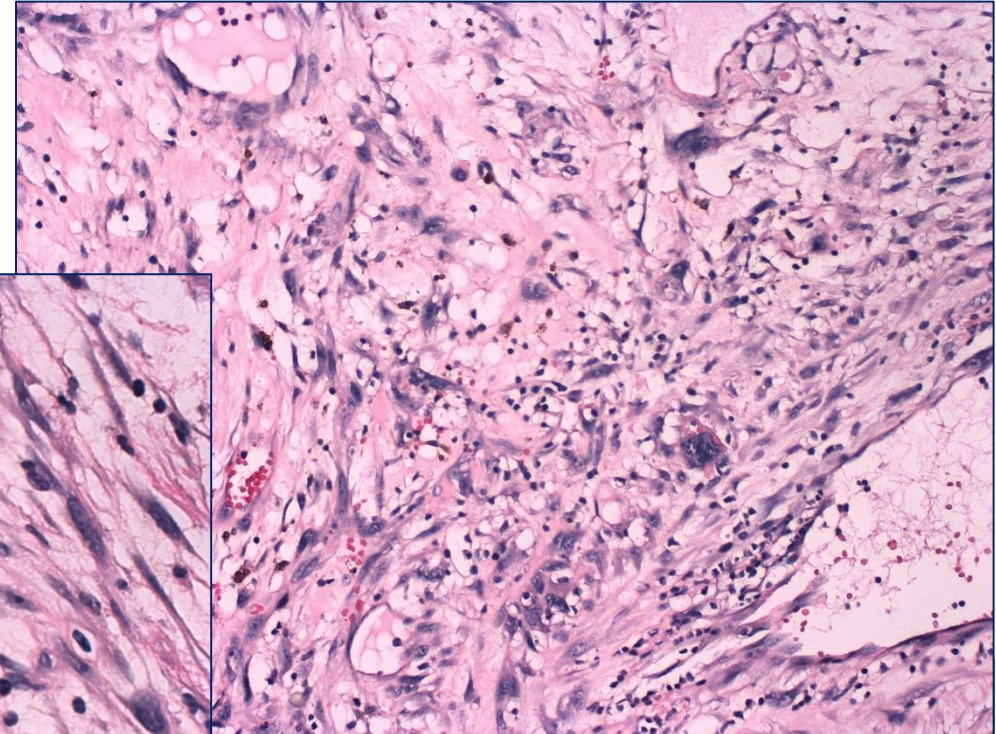
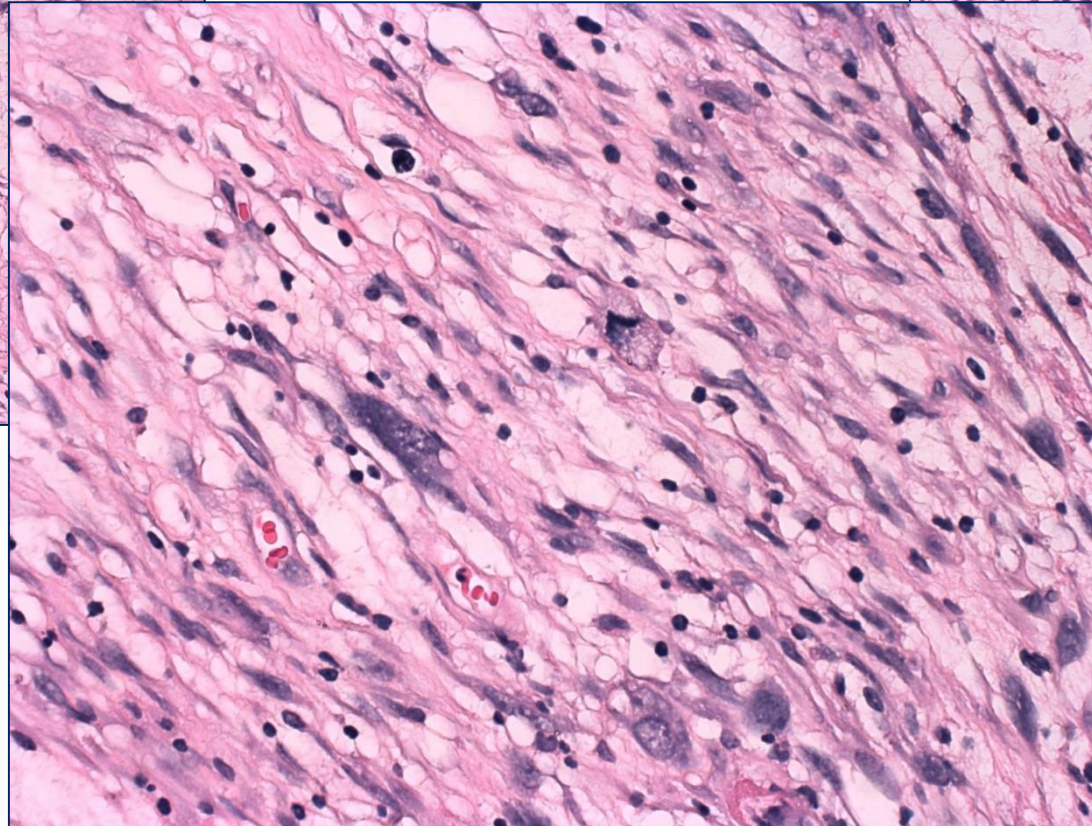
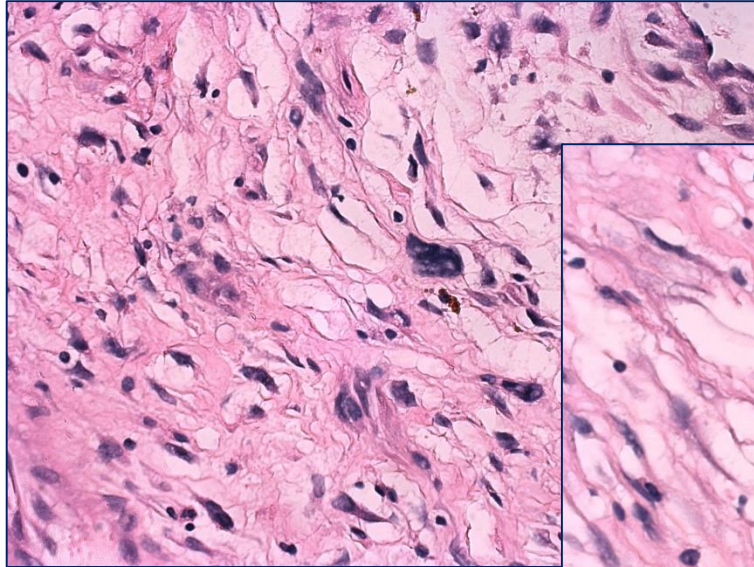
definitívna histológia – mitózy



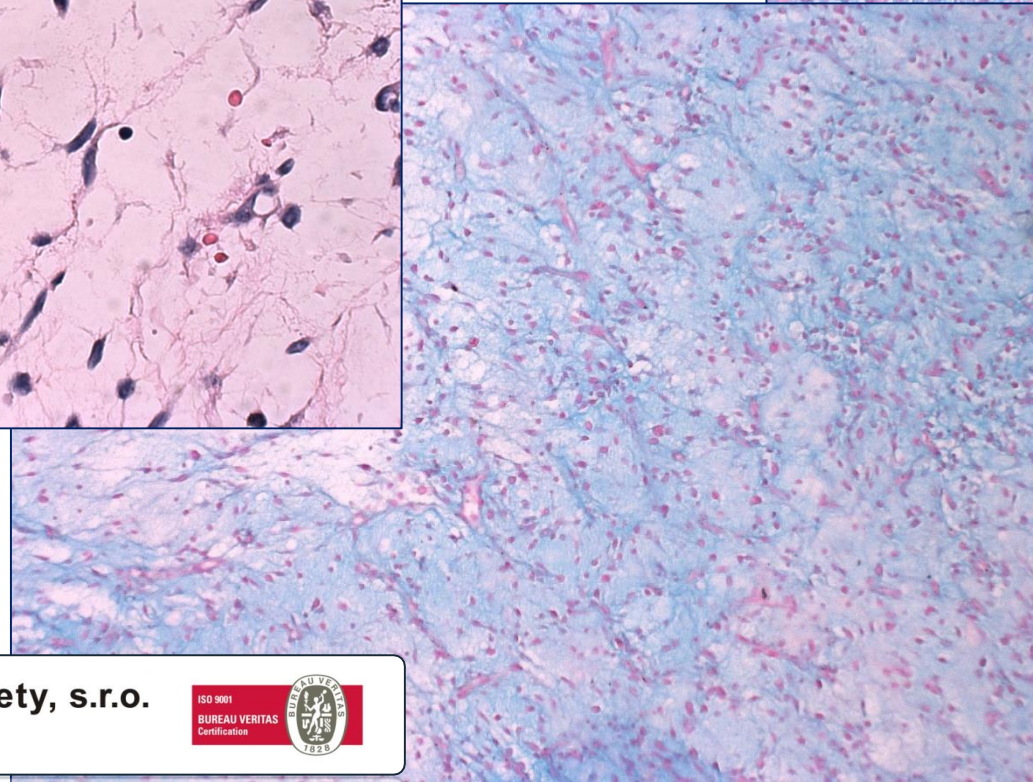
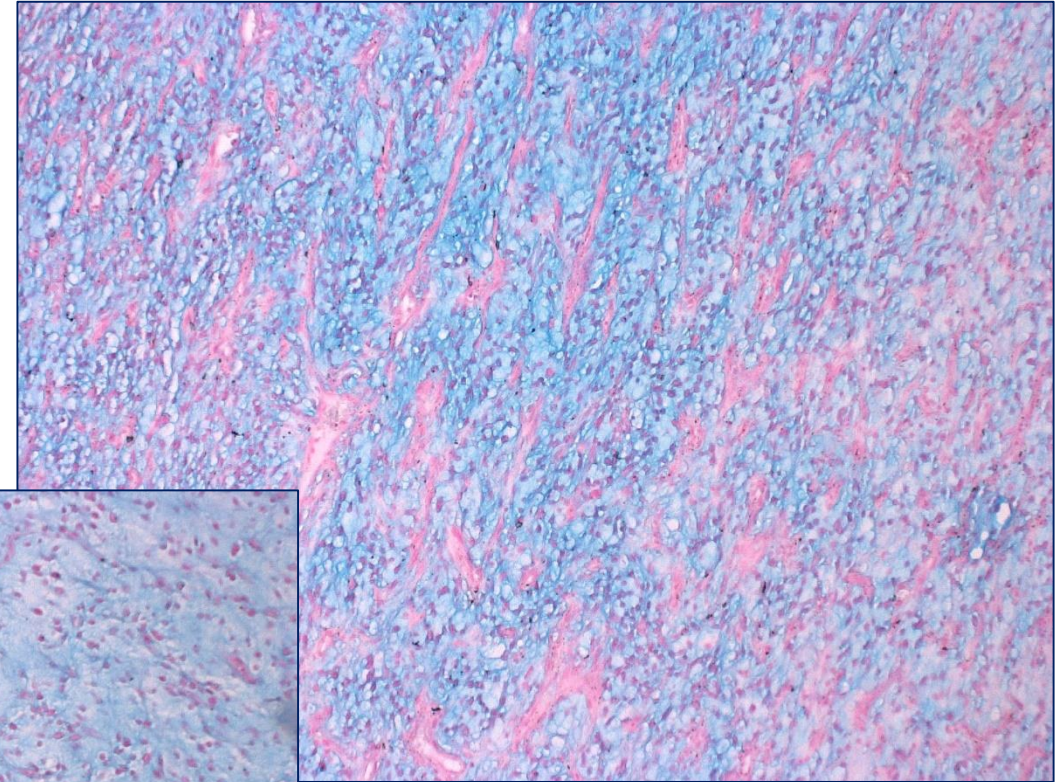
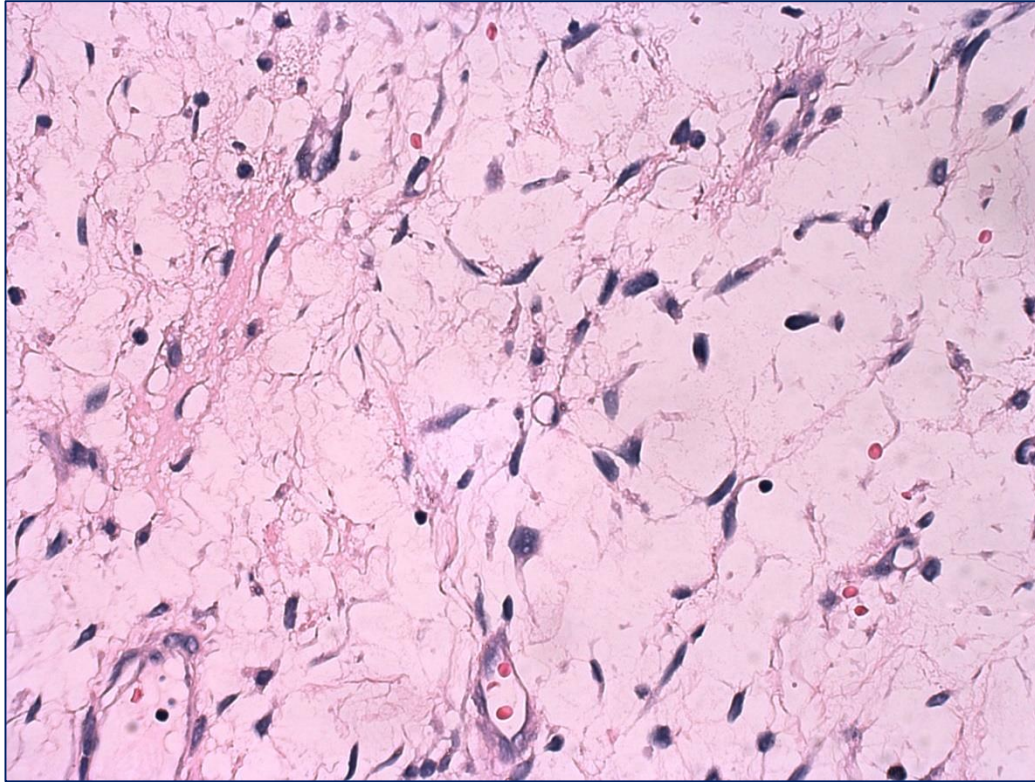
definitívna histológia – mitózy



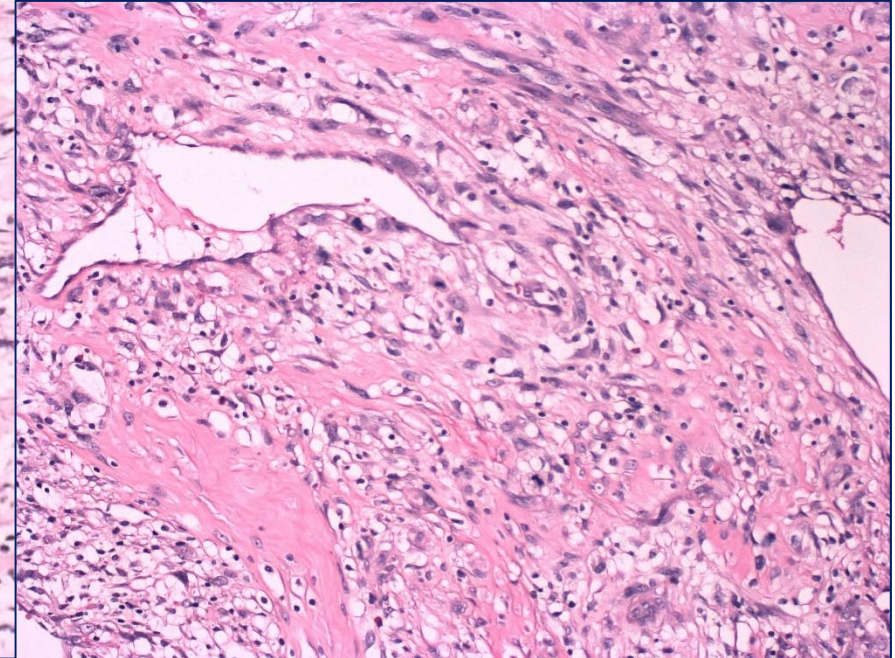
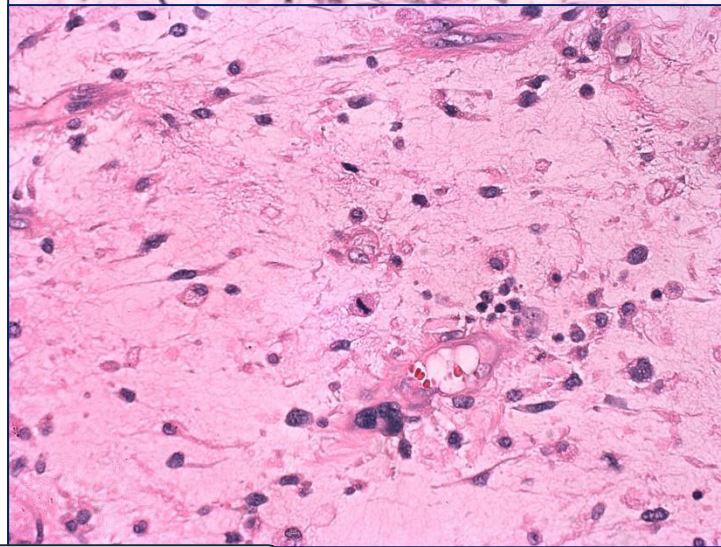
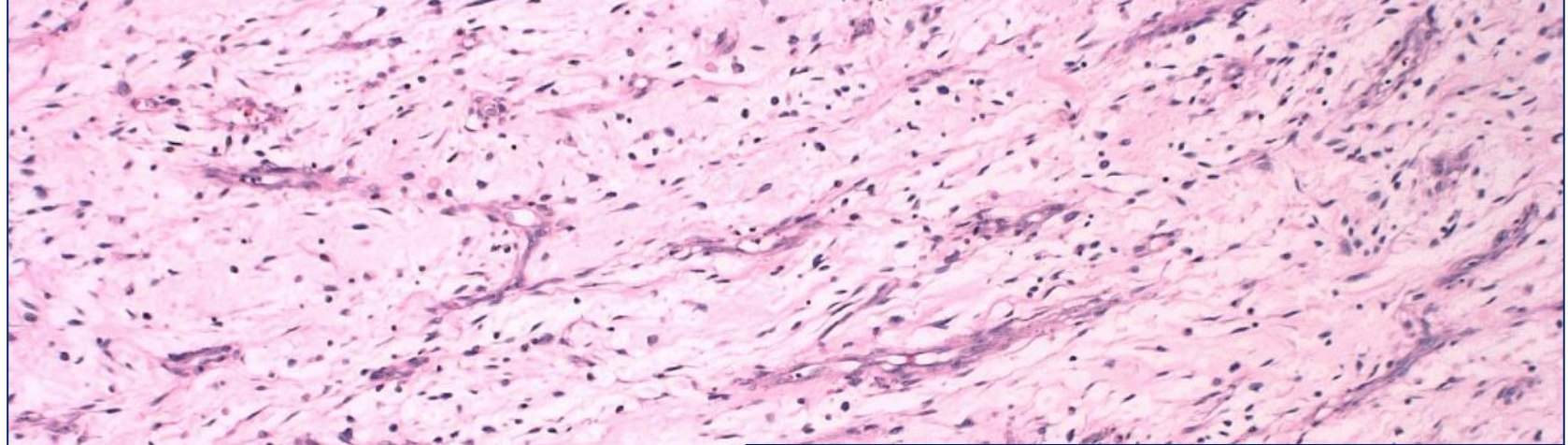
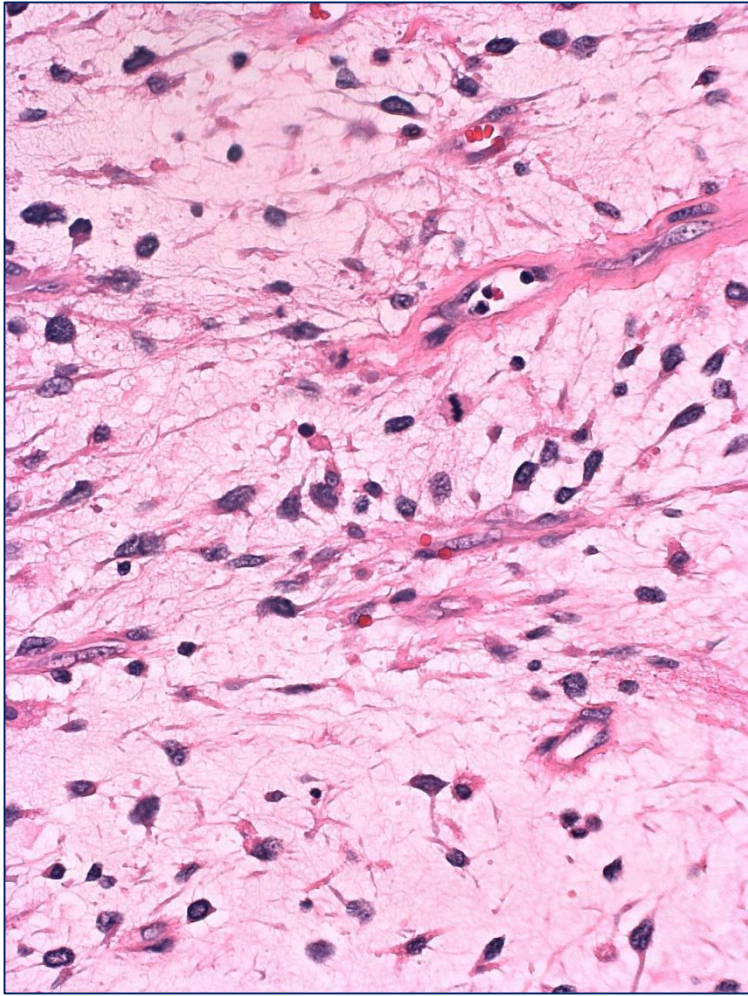
definitívna histológia – celulárna atypia



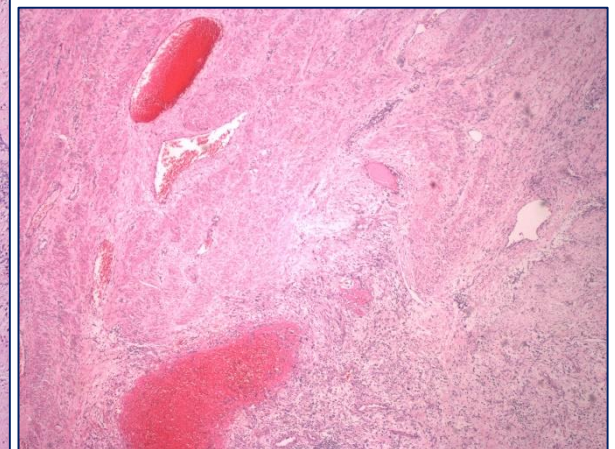
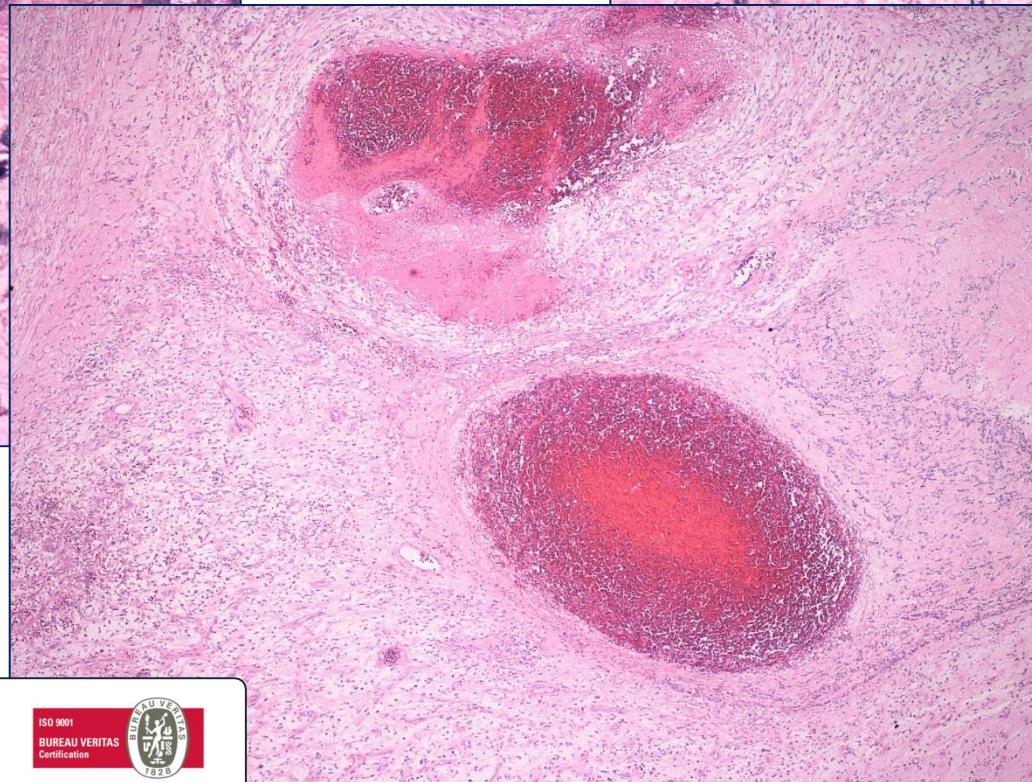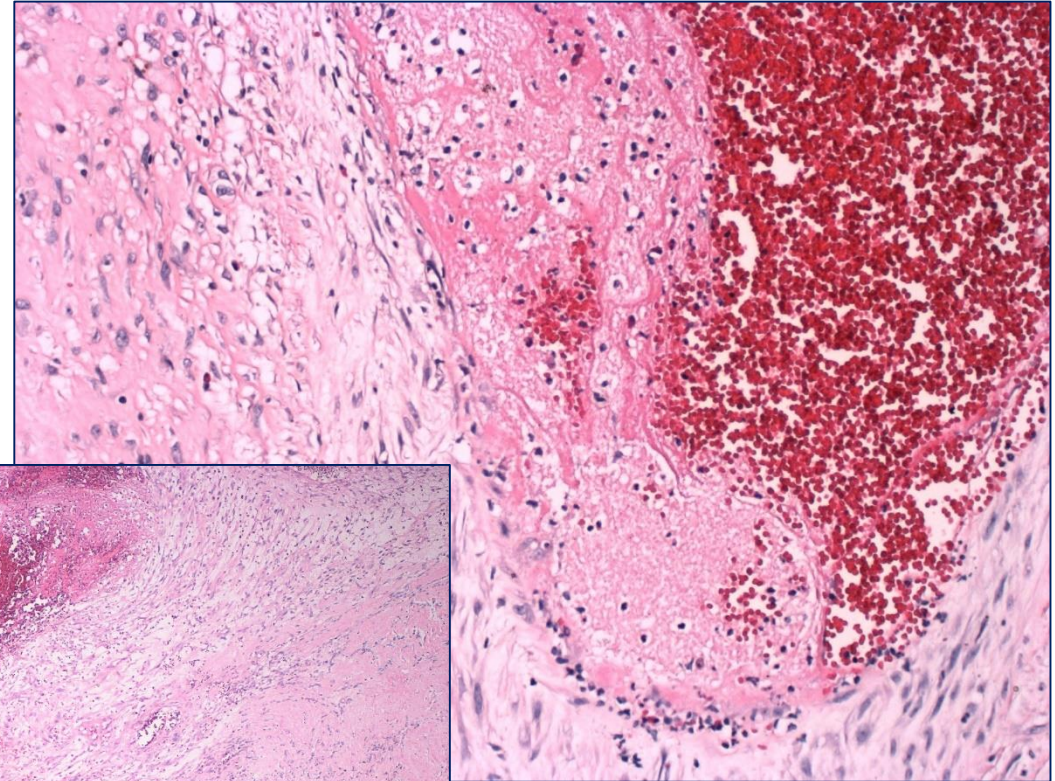
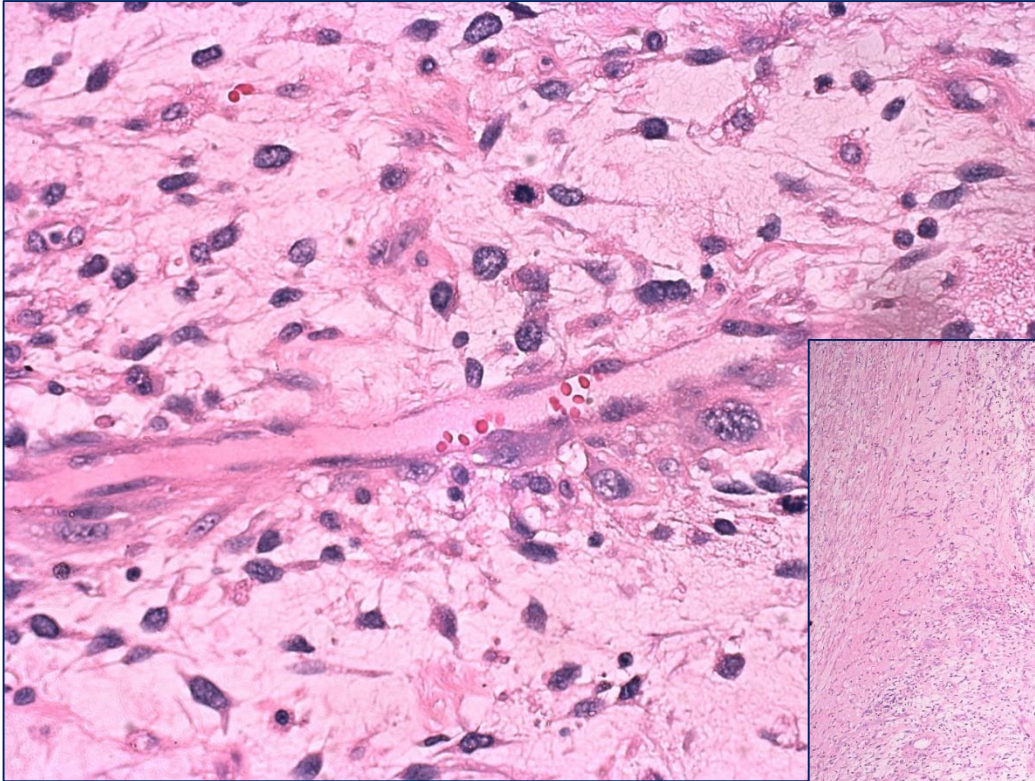
definitívna histológia – myxoidné zmeny



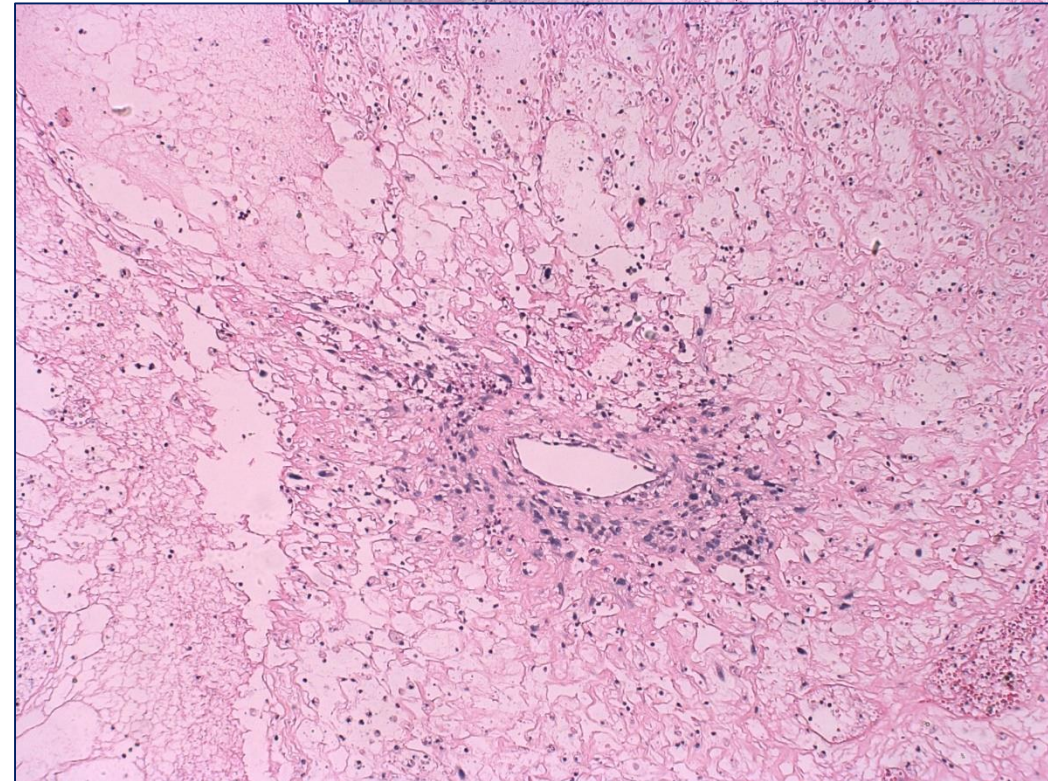
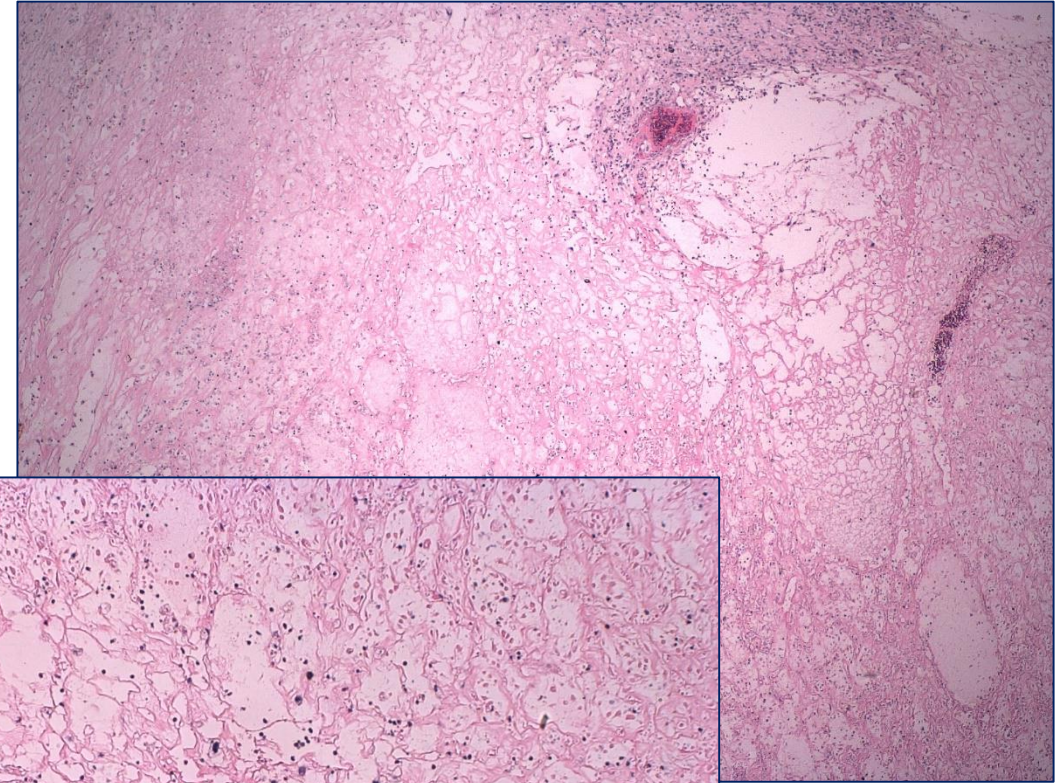
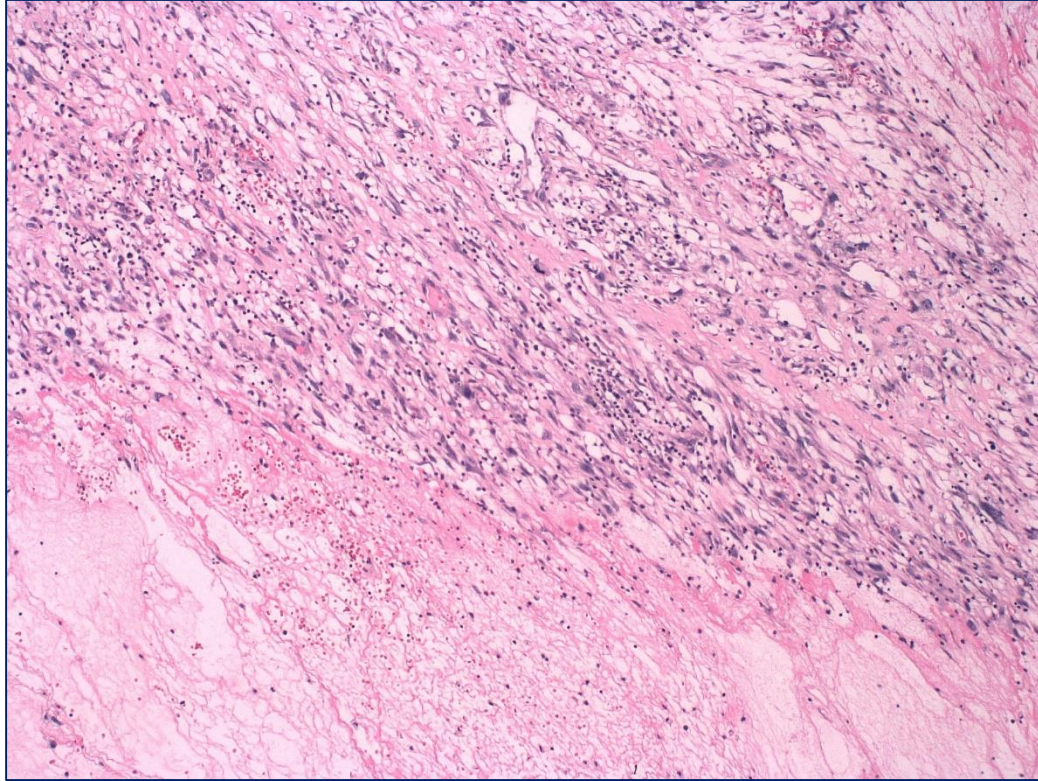
definitívna histológia – vaskularita



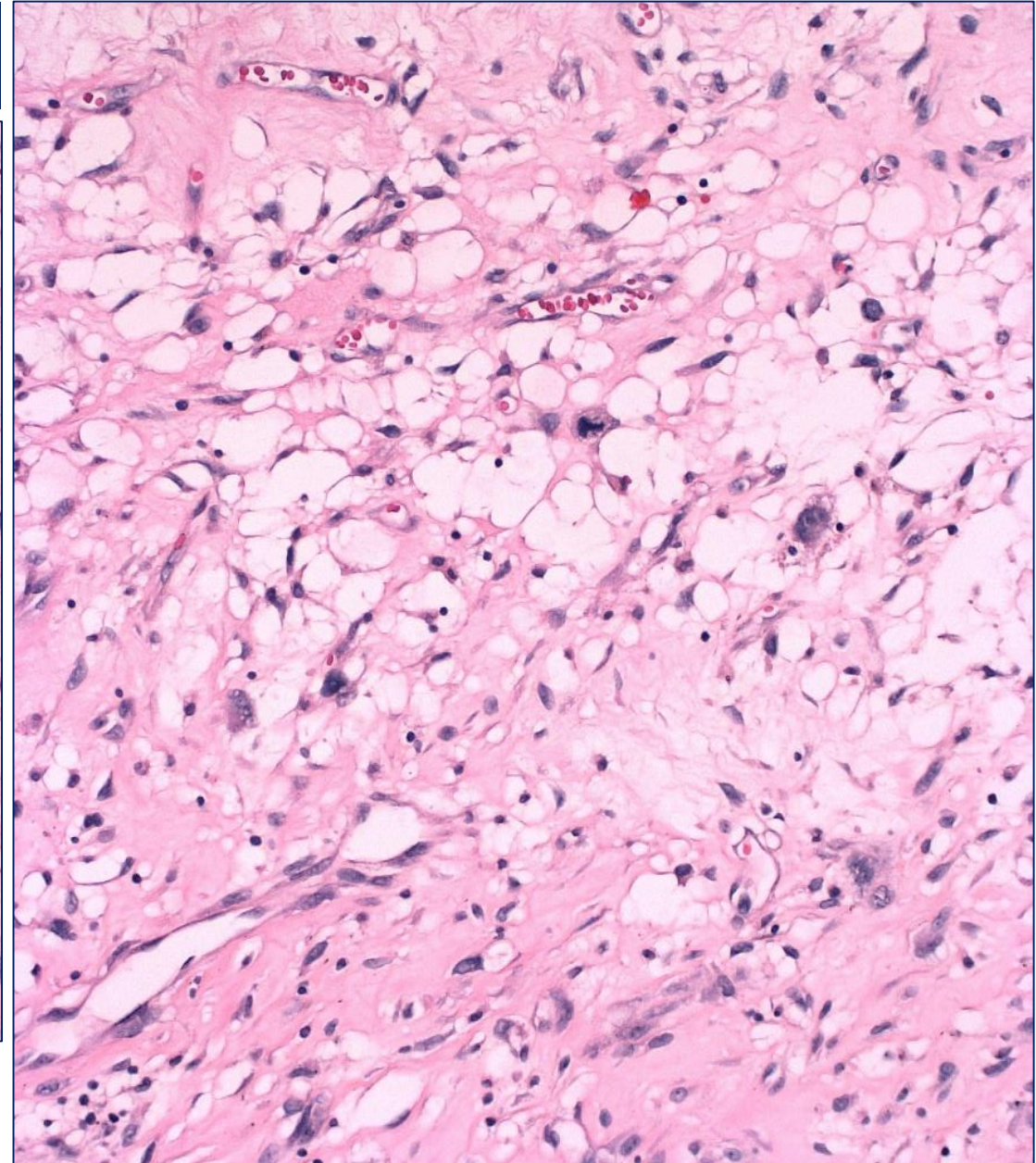
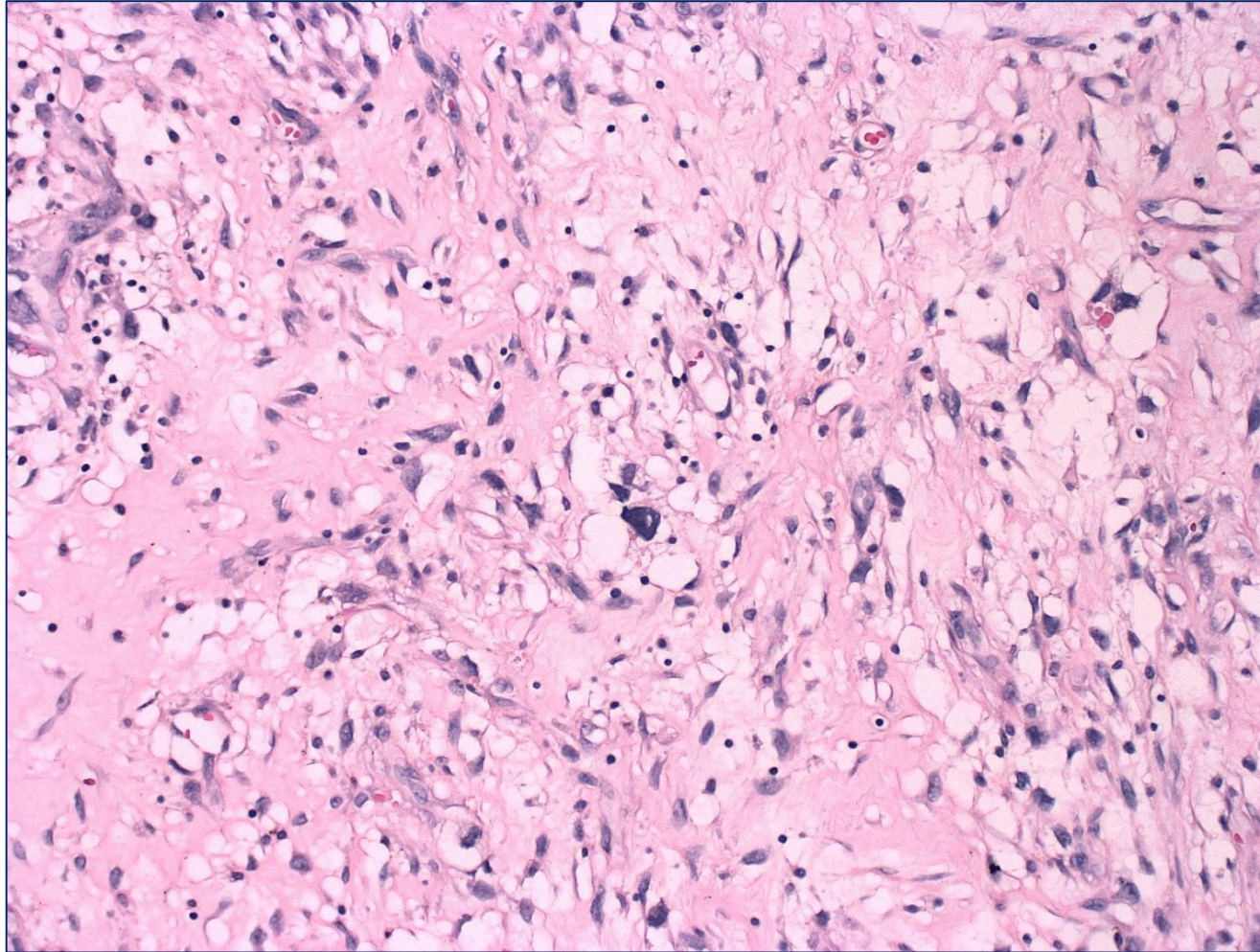
definitívna histológia – vaskularita



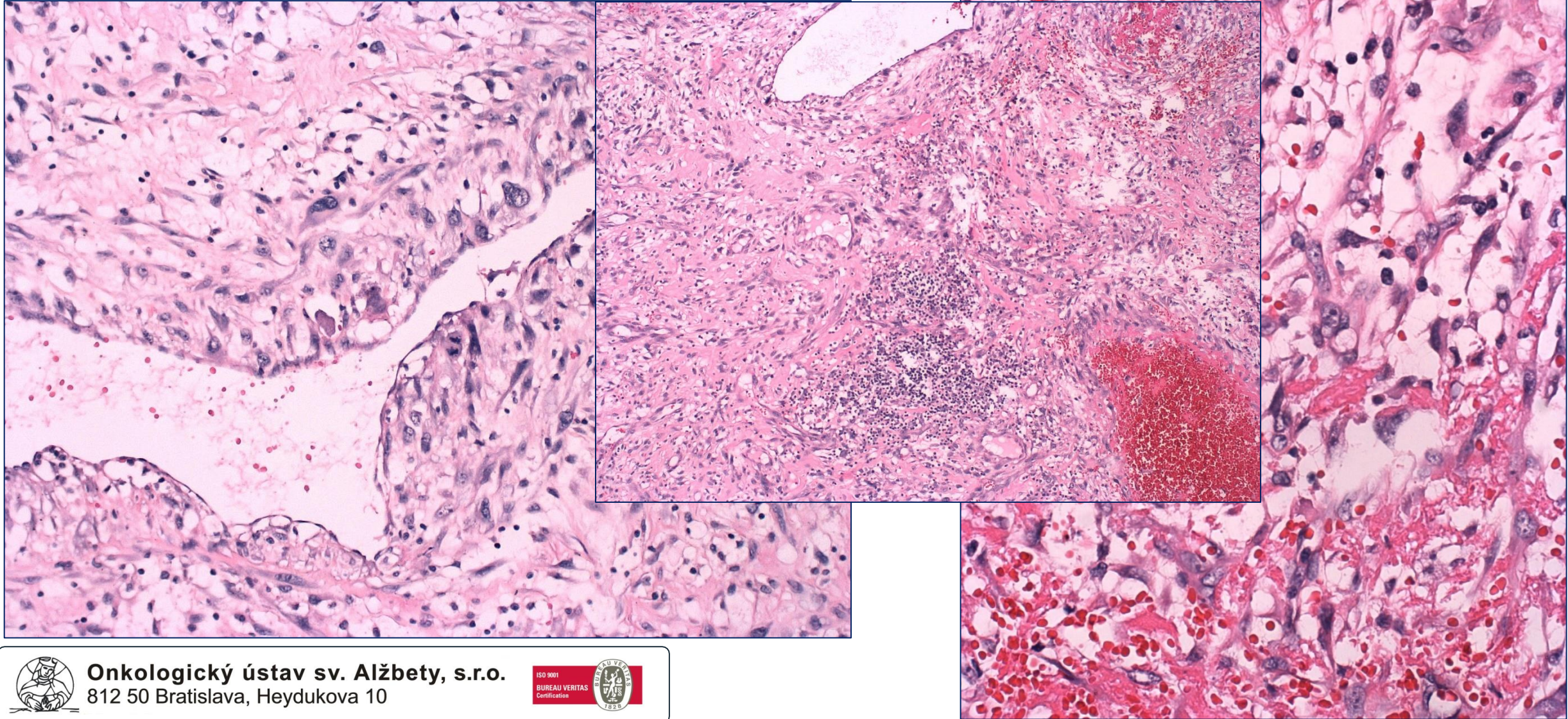
definitívna histológia - nekrózy



definitívna histológia – vakuolizované bb



definitívna histológia – ostatný nález



definitívna histológia – ostatný nález

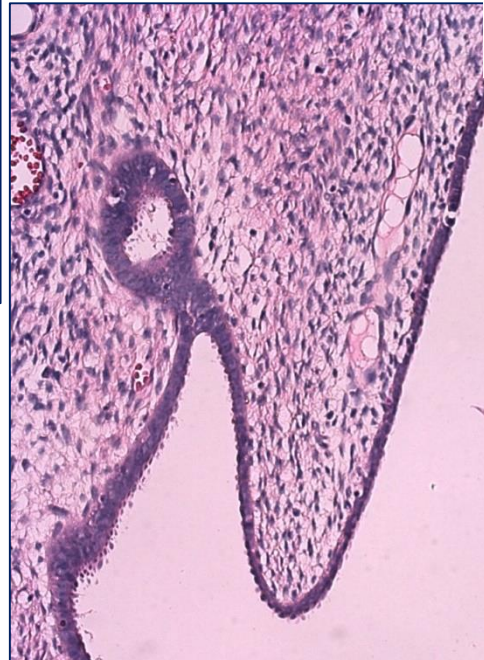
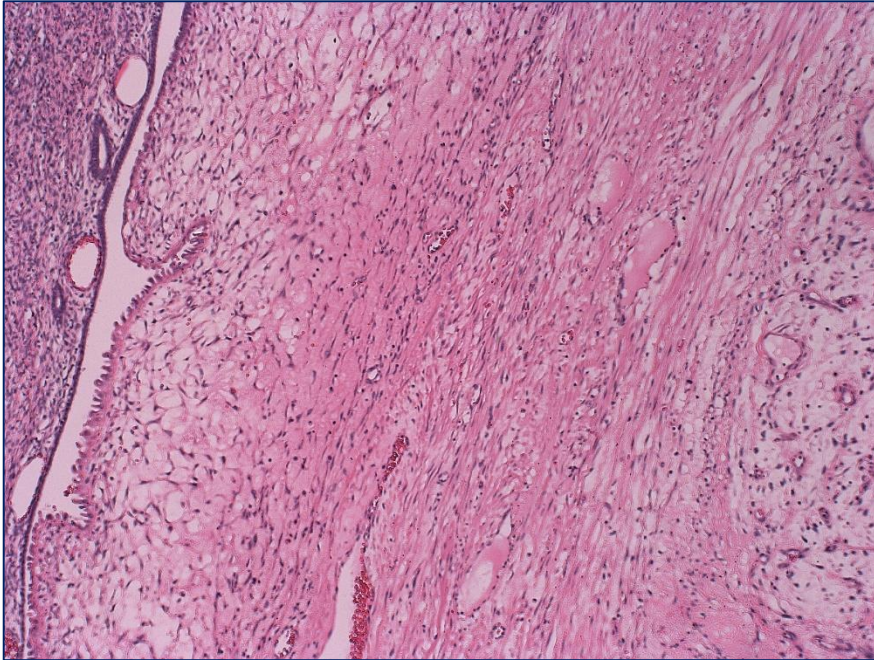


Table 7.2 Hobnail cells in the endometrium

Hobnail cell metaplasia (idiopathic)

Isolated finding

Within polyps and/or papillary proliferations

Arias-Stella reaction

Secondary to:

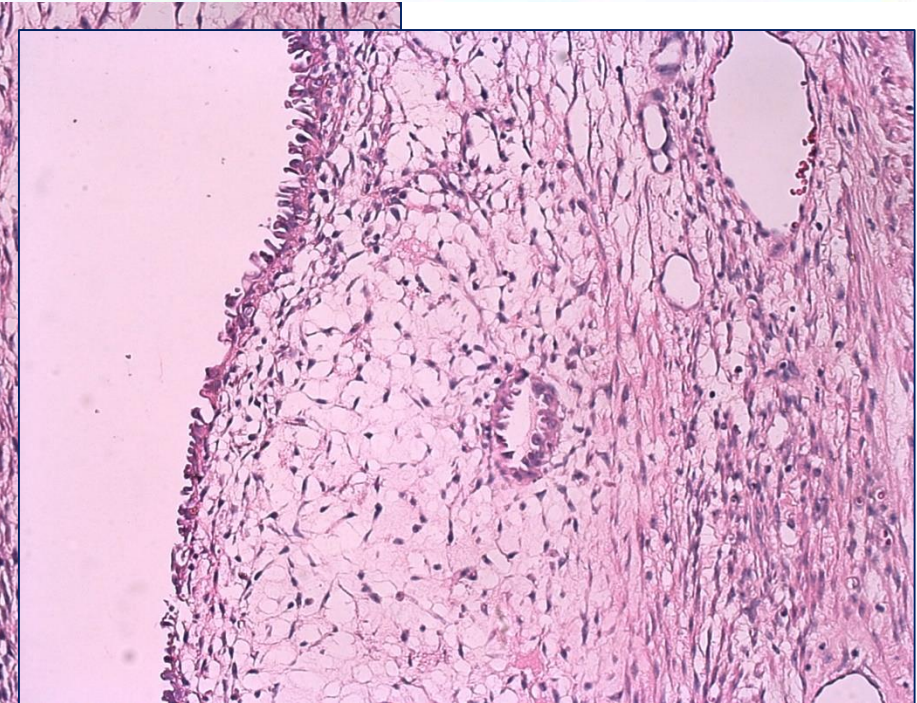
Recent curettage

Ischemia (within an infarcted polyp or adjacent to a thrombosed sinusoid)

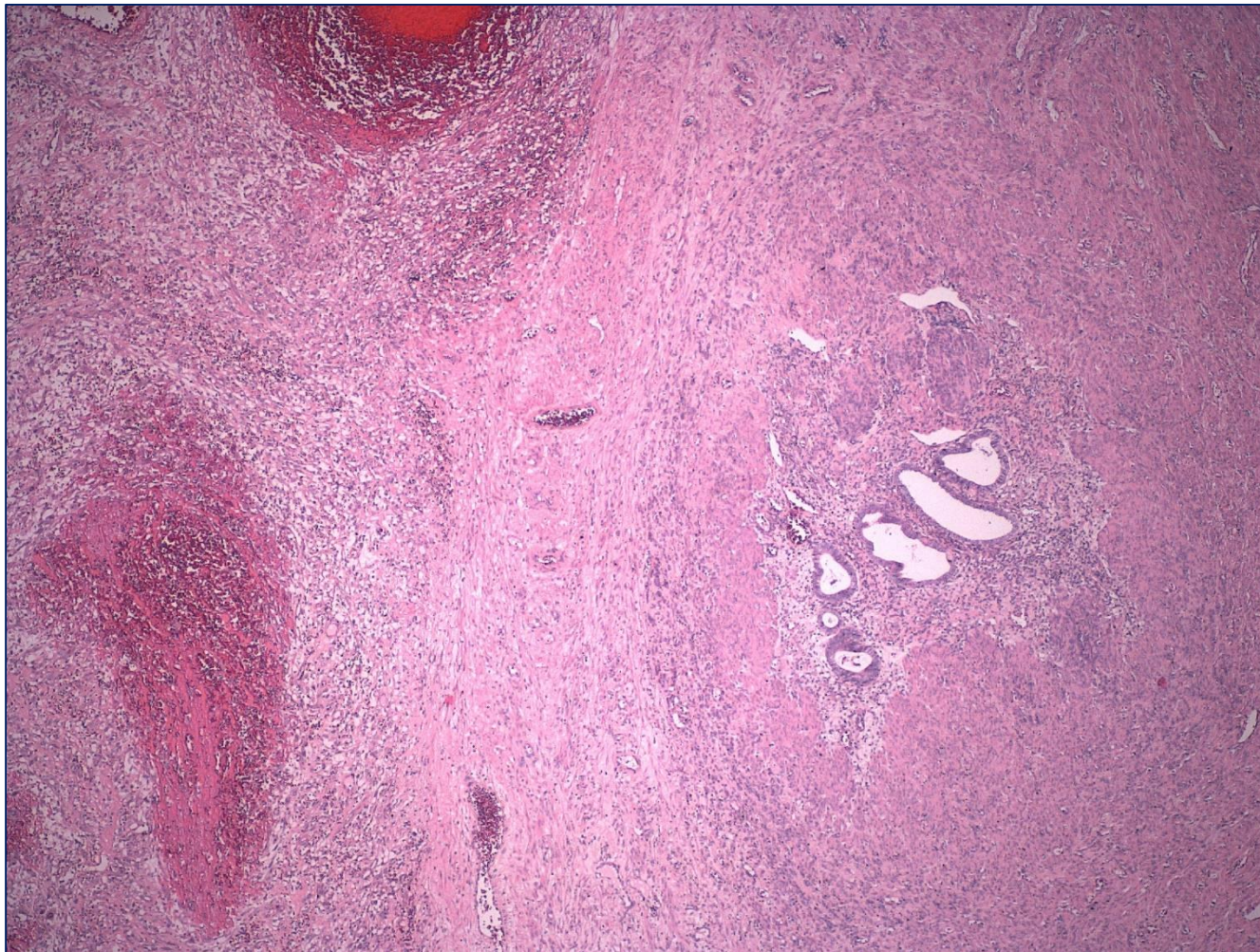
Chronic endometritis

Intrauterine contraceptive device

Radiation



definitívna histológia – ostatný nález



cytológia – výplach DB

MUDr. J.Jozefáková, M.I.A.C.:

- reprezentatívny materiál
- v náteroch z obsahu 100ml kalnej ružovej tekutiny sú útržky mezotelu bez atypií, malígne elementy nie sú prítomné



klinicko-morfologická rekapitulácia

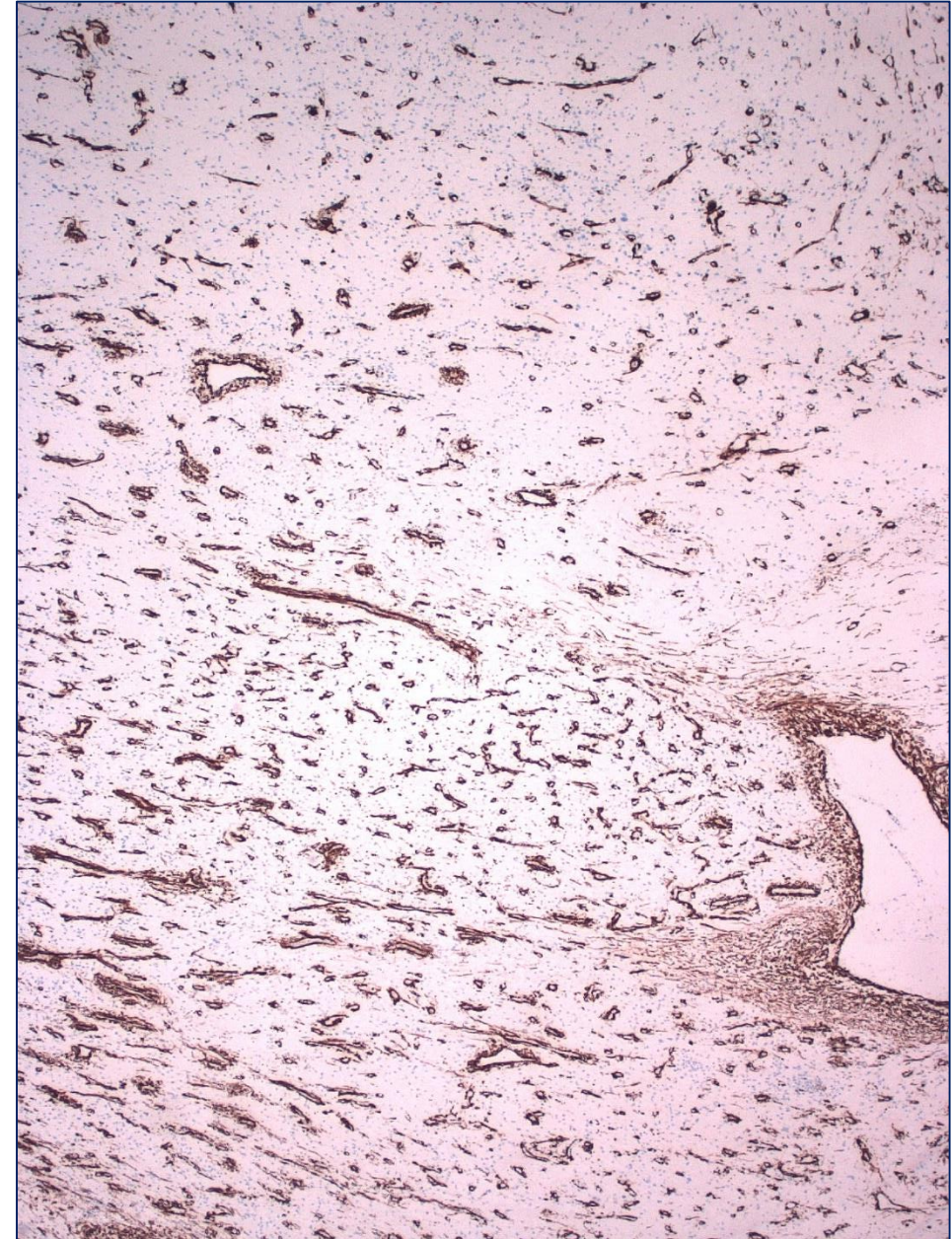
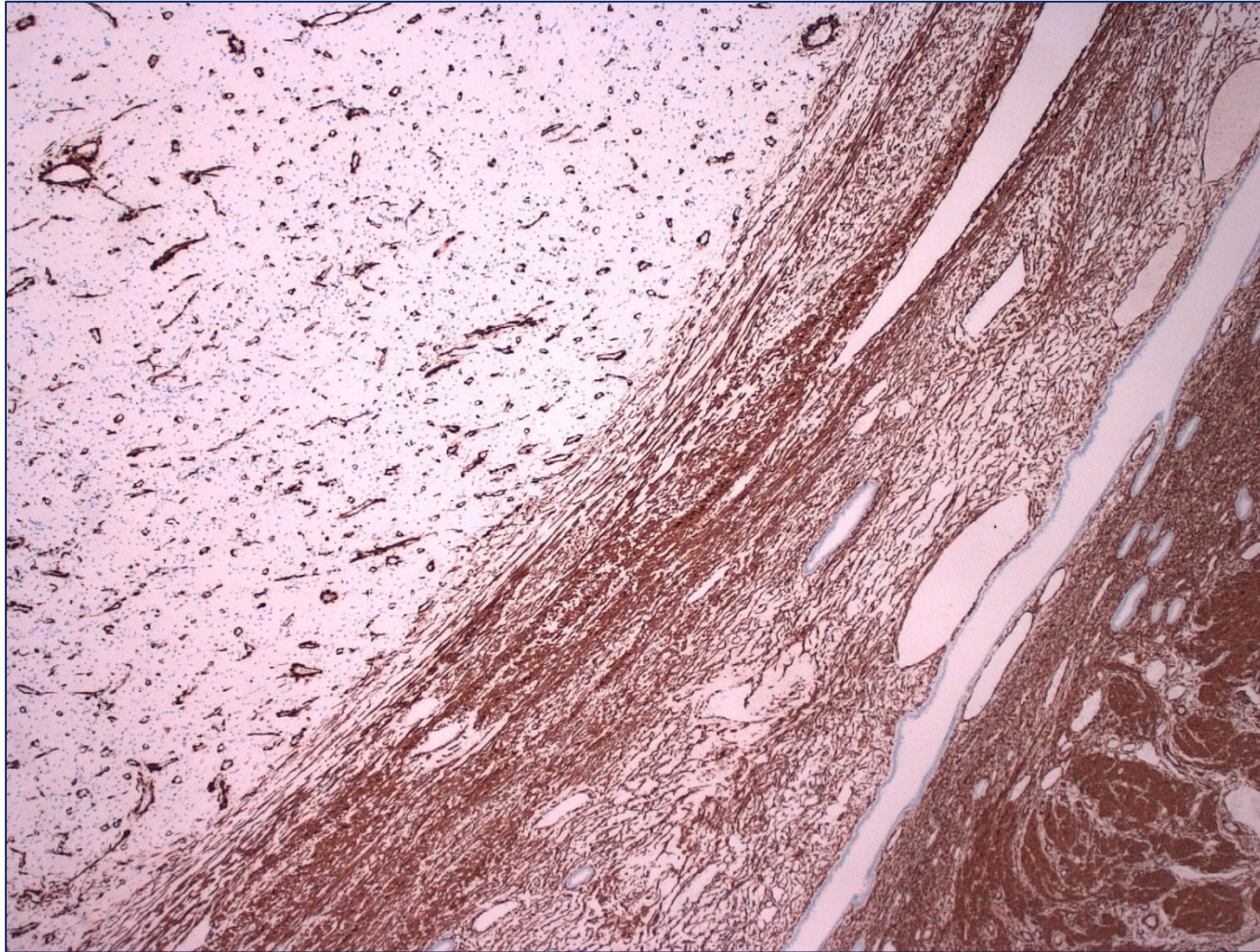
- **PM** žena
- **čistý mezenchýmový tumor** (bez epitelových štruktúr)
- oválno- vretenobunkový, s pleomorfiou, vakuolizované bunky
- **zvýšená mitotická aktivita**
- **myxoidné črty**
- **zvláštna vaskularita**
- regresívne zmeny: krvácania, edém, nekrózy



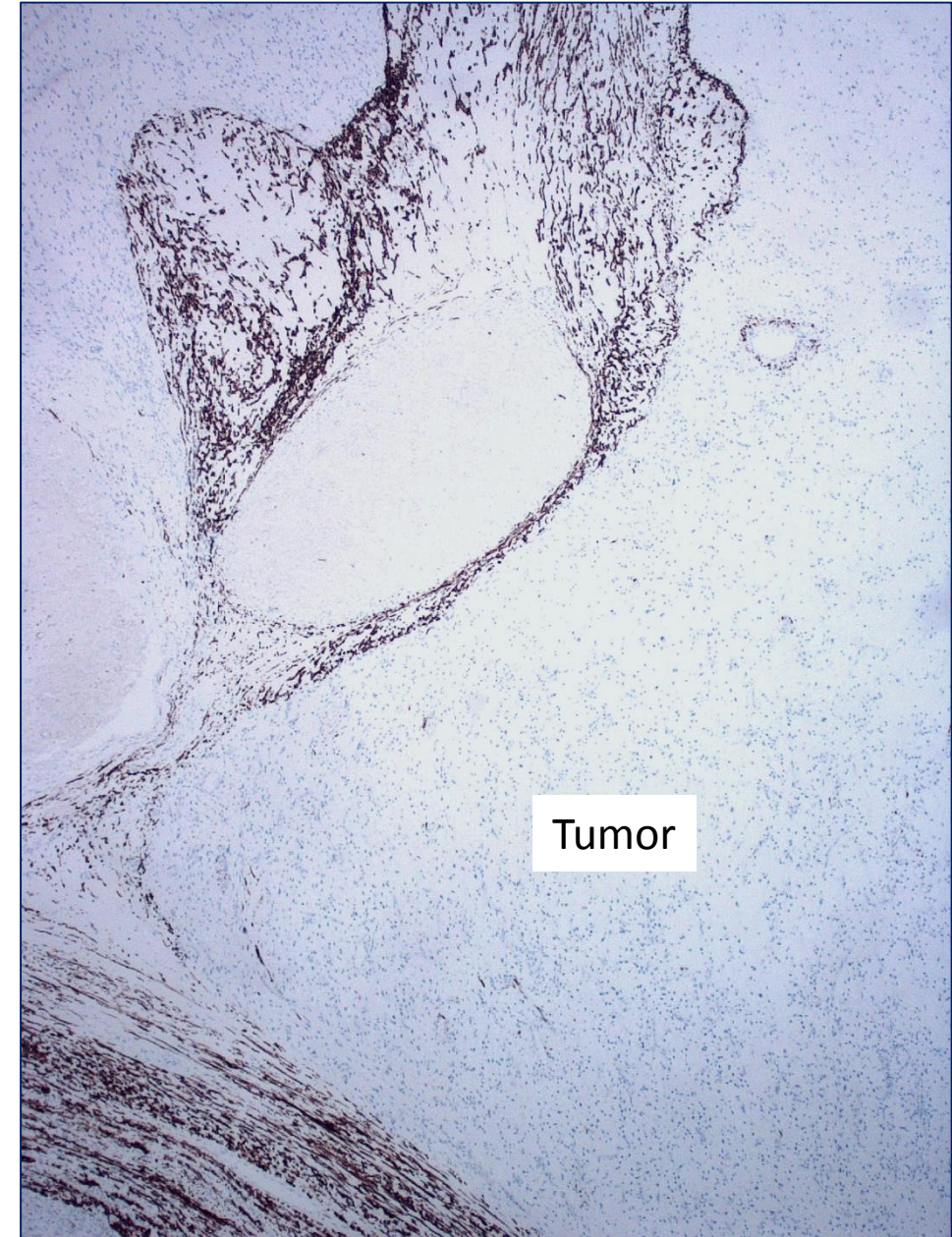
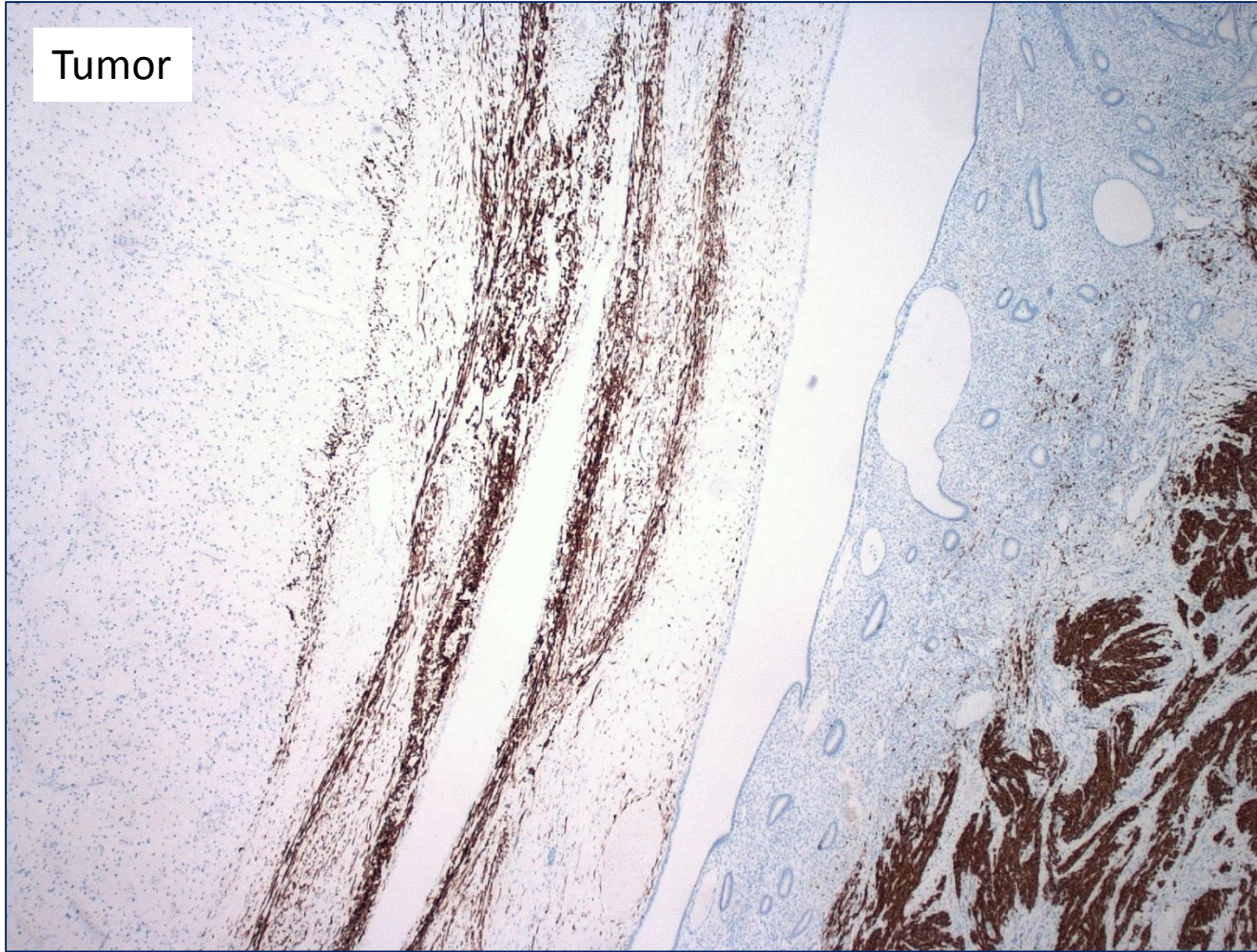
SARKÓM...

... a Vaša dg?

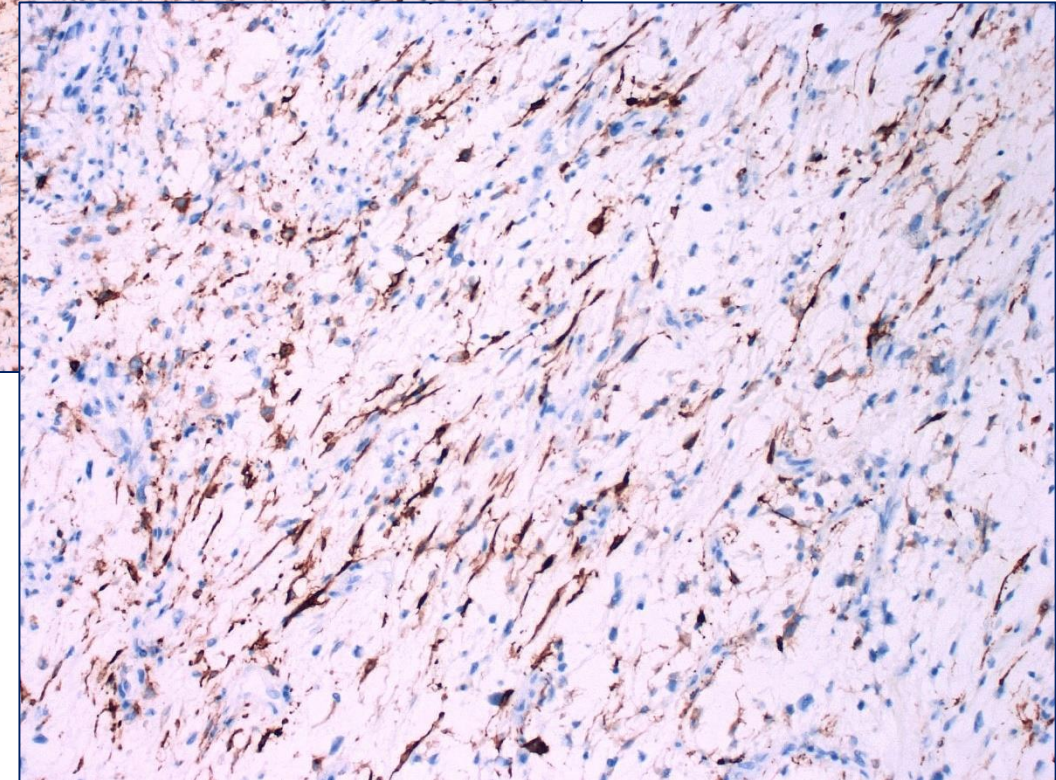
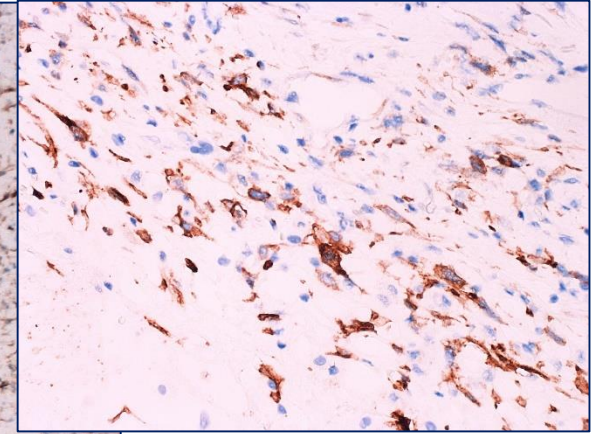
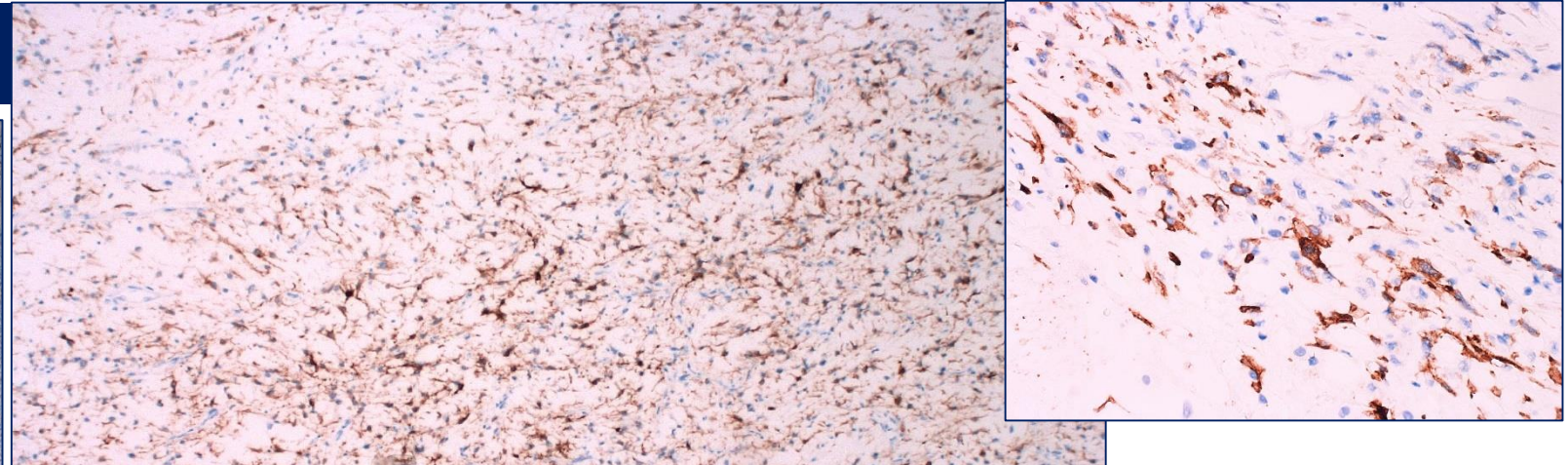
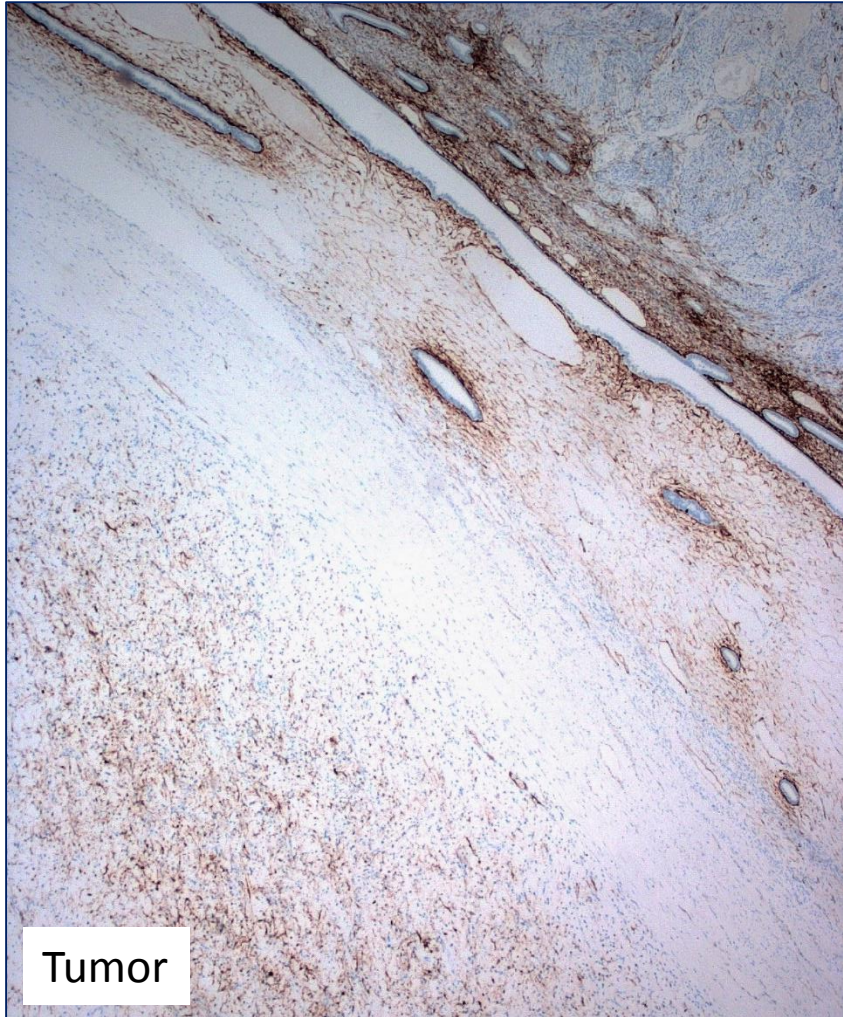
IHC - SMA



IHC - dezmín



IHC – CD10



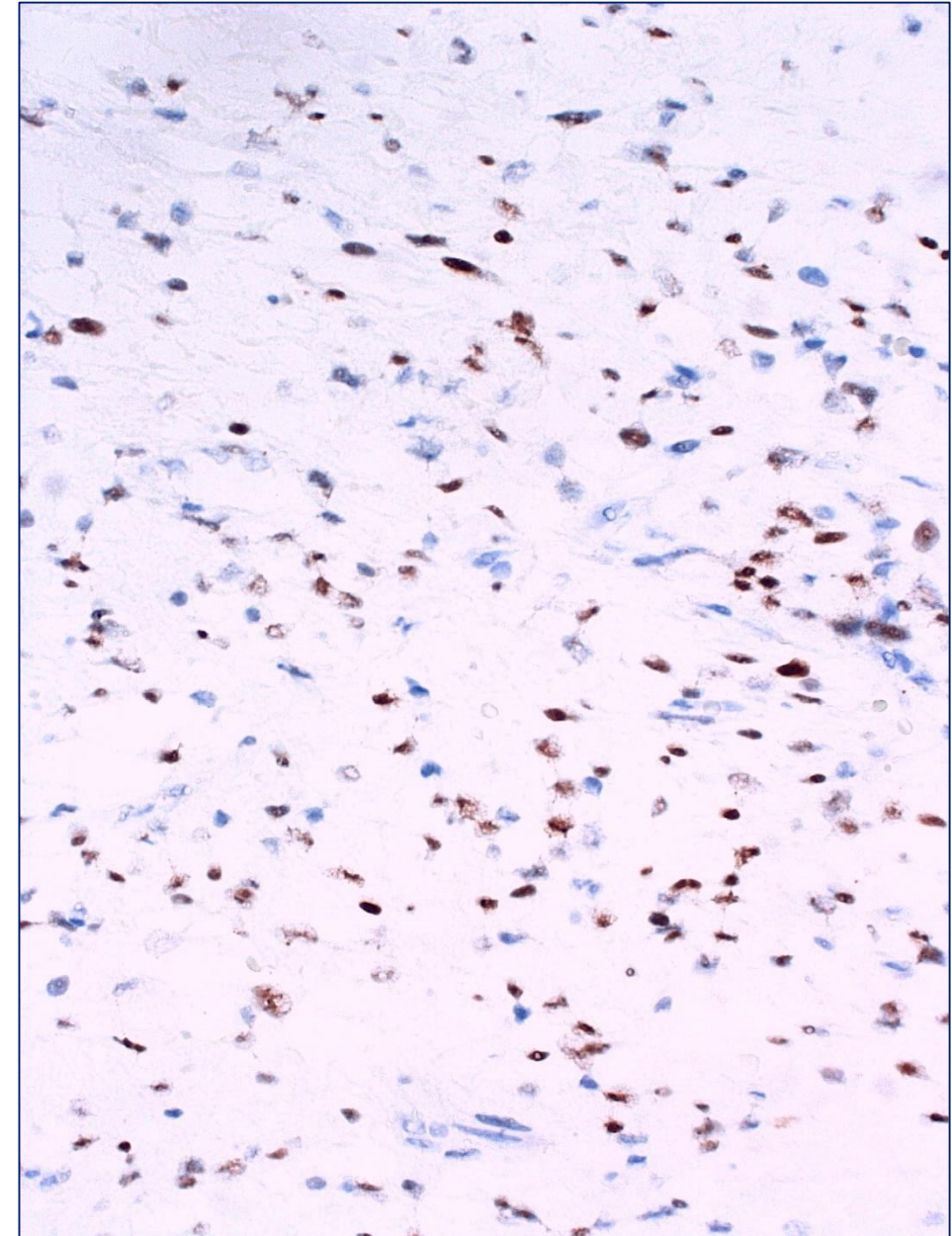
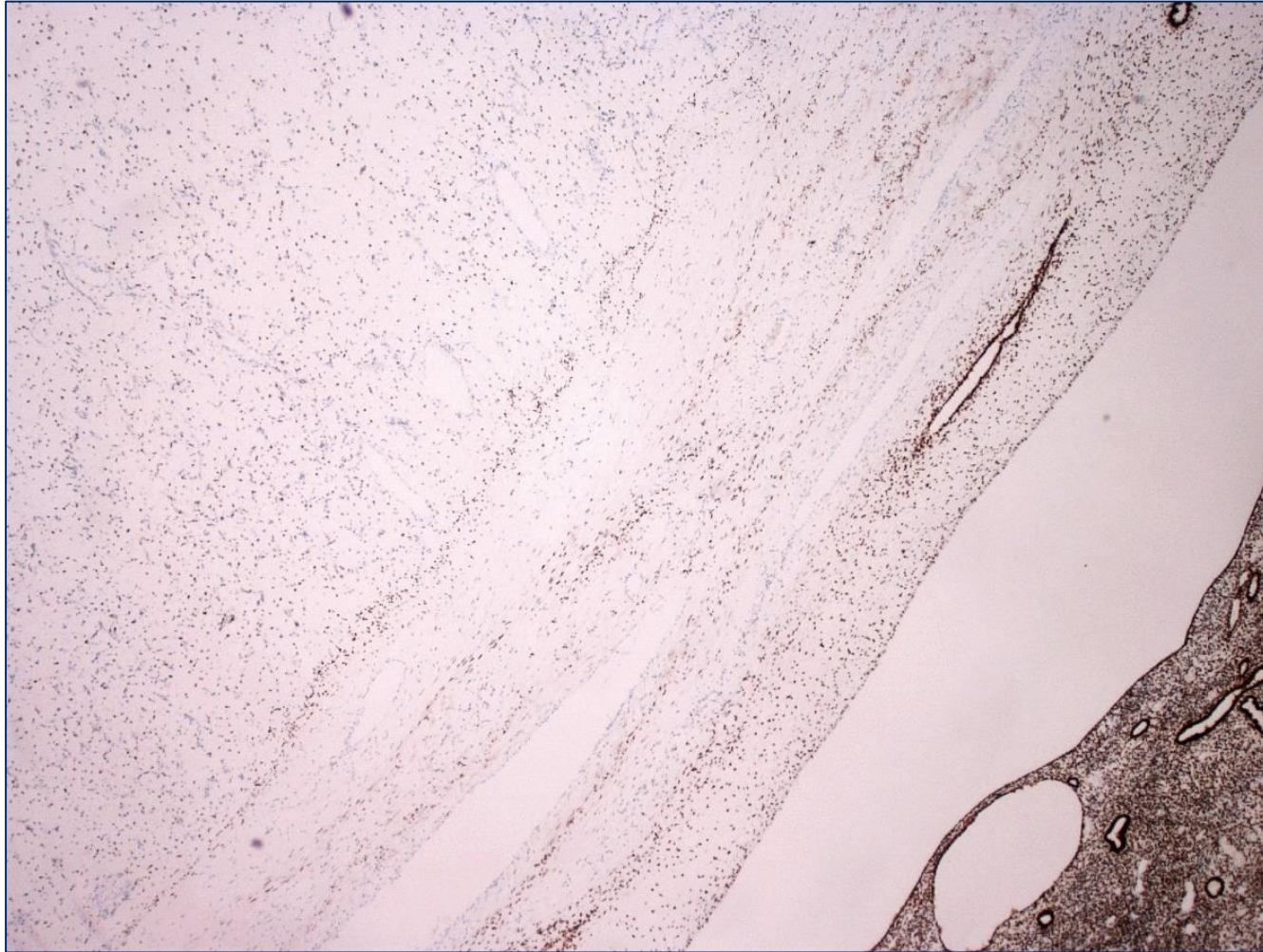
Tumor



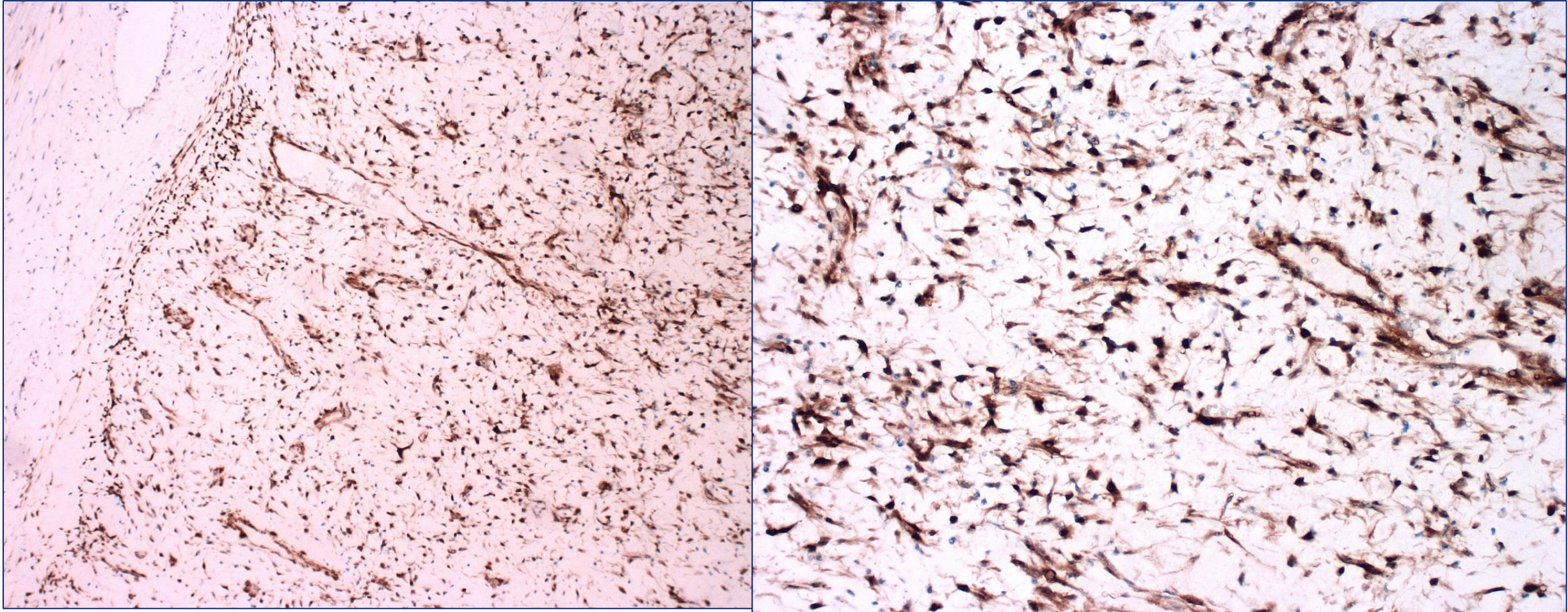
Onkologický ústav sv. Alžbety, s.r.o.
812 50 Bratislava, Heydukova 10



IHC - ER

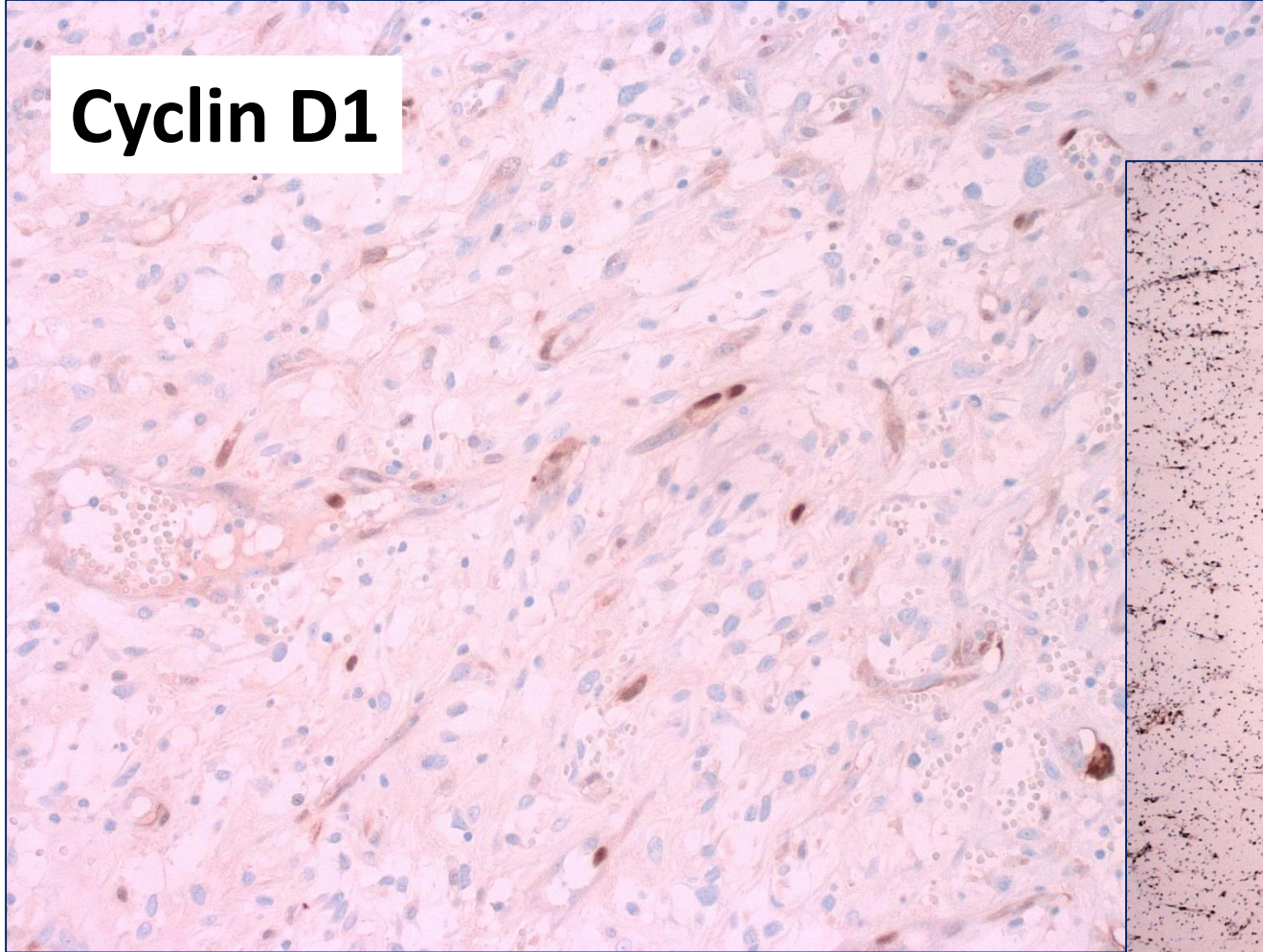


IHC – CDK4

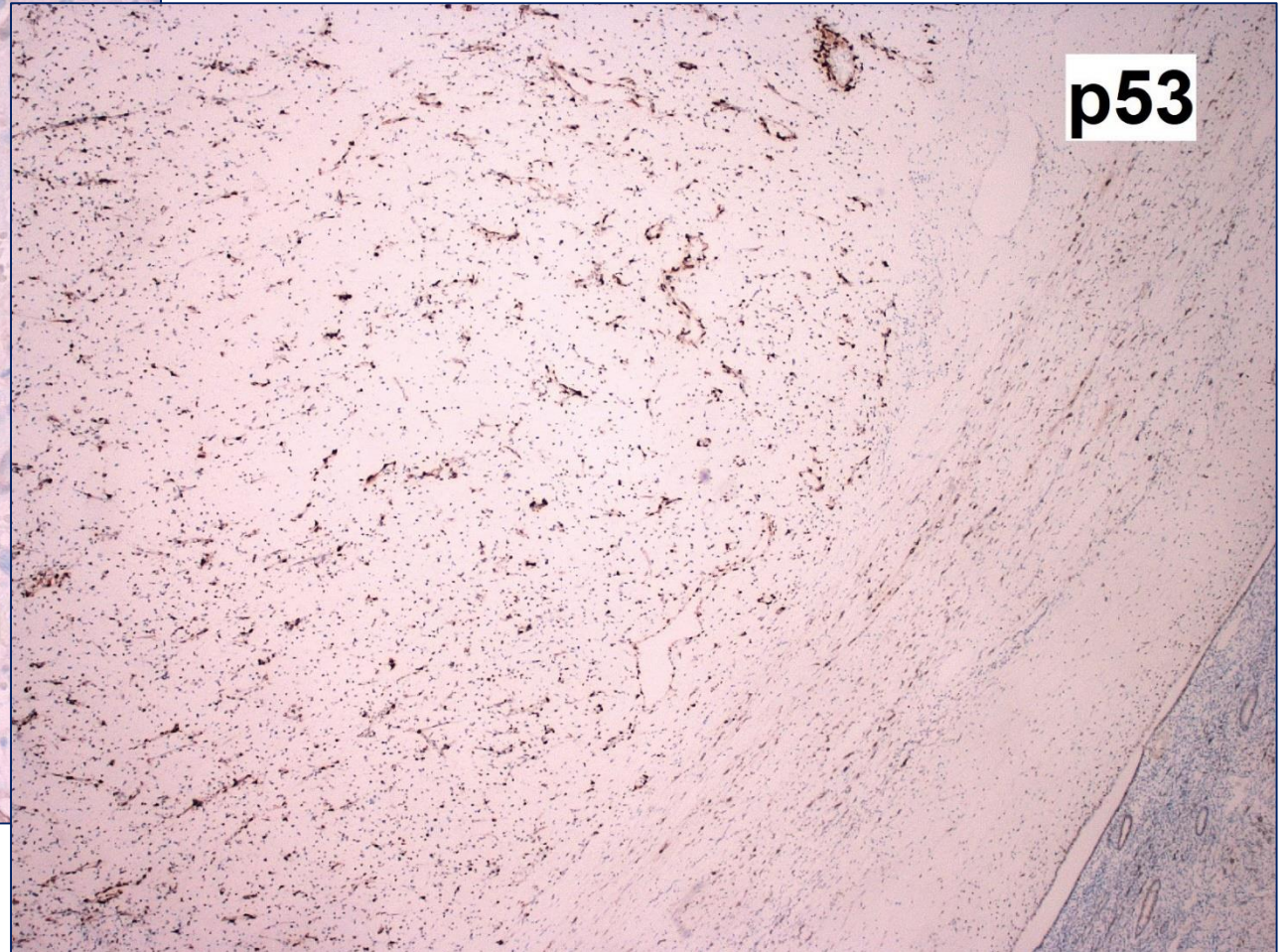


IHC

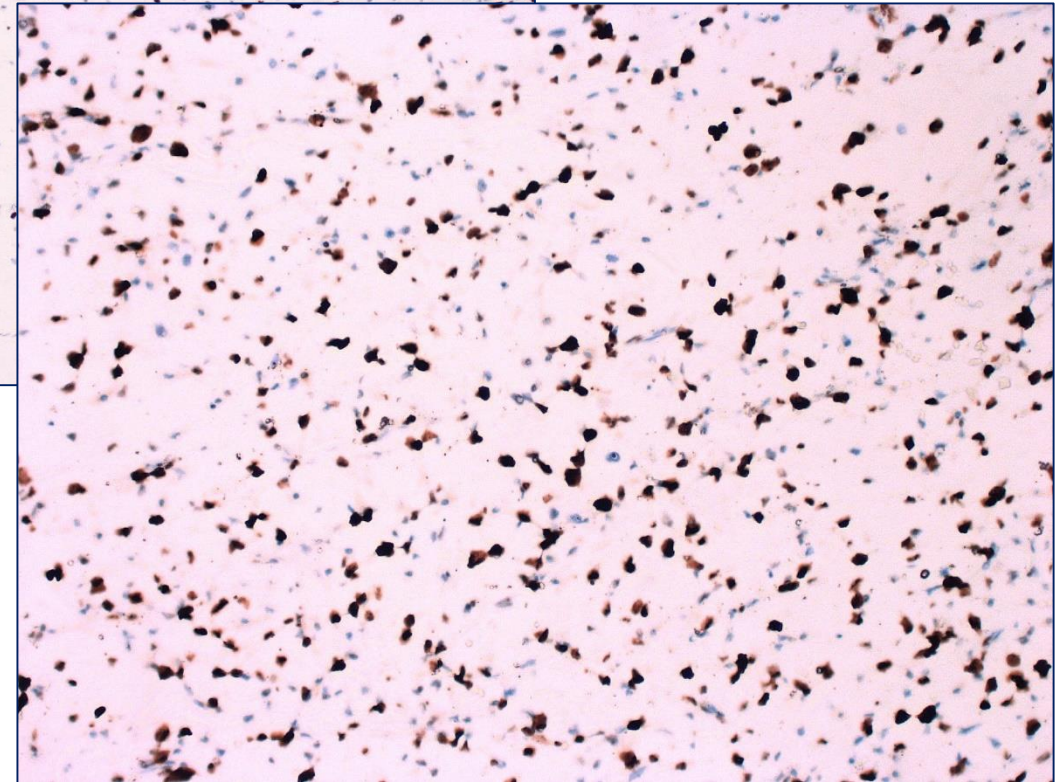
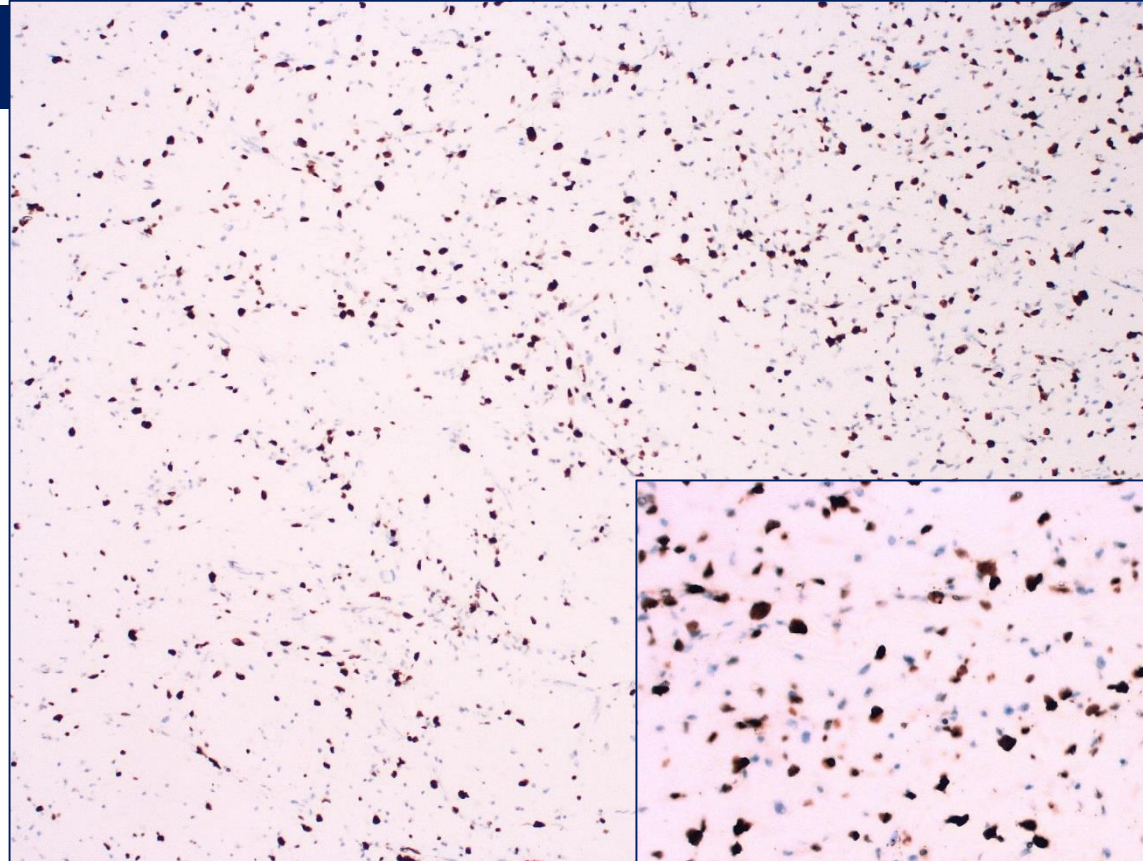
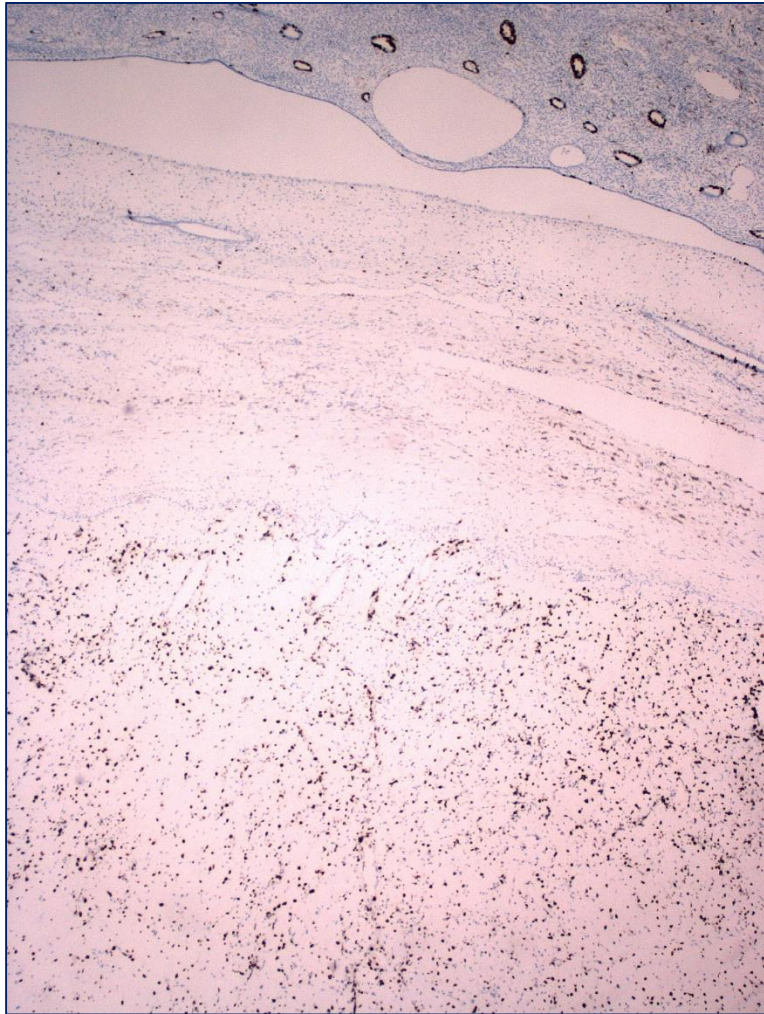
Cyclin D1



p53



IHC – Ki67



IHC - rekapitulácia

pozitivita

- vimentin
- CDK4
- CD10 (slabá a fokálna)
- ER (cca 50%)
- p53
- Cyclin D1 (slabá expresia do 5%)

Ki67 index cca 50%

negativita

- DEZMIN; SMA; h-caldesmon
- AE1/AE3; EMA; HMW-CK
- S100; HMB45; Melan A
- CD117; CD34
- PR
- β -catenin; MDM2



Genetické vyšetrenie (OLG, NOÚ Bratislava)

FISH

- *FUS* (16q11.2) zisky *FUS* 15%
- *DDIT3* (12q13) zisky *DDIT3* 21%

Prítomné len numerické zmeny vo forme ziskov génov ***FUS* (15%)** a ***DDIT3* (21%)**.

Prestavby génov *FUS* a *DDIT3* (CHOP), ktoré sú predpokladom fúzie *FUS/DDIT3* = t(12;16) neboli zaznamenané

Molekulová genetika

- vo vyšetrenej vzorke nebola identifikovaná prítomnosť žiadneho transkriptu z fúzných génov uvedených v tabuľke (t.j. *FUS-DDIT3*)

vylúčili myxoidný LS



Klinicko-morfologická rekapitulácia

- PM žena
- čistý mezenchýmový tumor (bez epitelových štruktúr)
- oválno- vretenobunkový, s pleomorfiou, pseudolipoblasty
- zvýšená mitotická aktivita
- myxoidné črty
- vaskularita
- regresívne zmeny: krvácania, edém, nekrózy


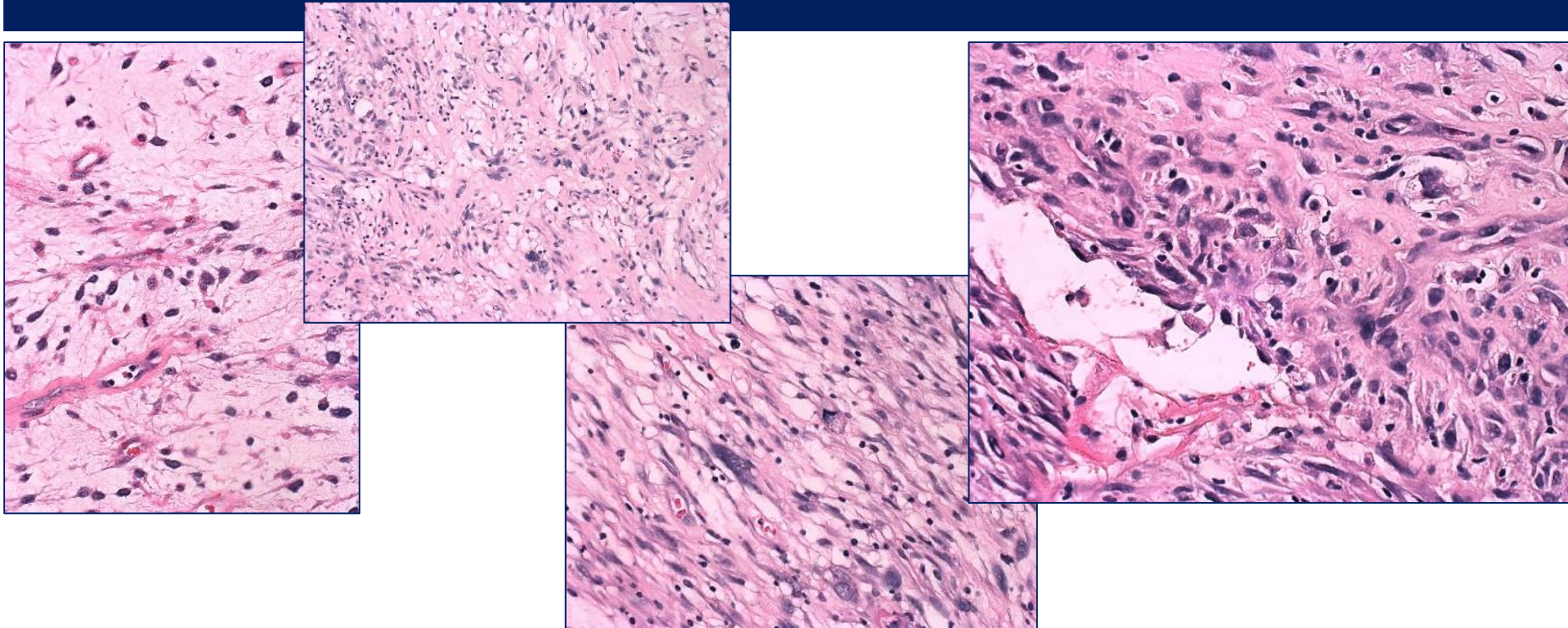
SARKÓM...

- **VIM+/CDK4+/CD10±/ER±**
- **↑ Ki67 index**
- negat. svalové, epitelové, melanómové markery
- negatívna genetika na myxoidný LS

... a Vaša dg?

Môj dg.záver:

Nediferencovaný sarkóm maternice
(s myxofibrosarkómovými črtami); M:8805/3; štádium I A



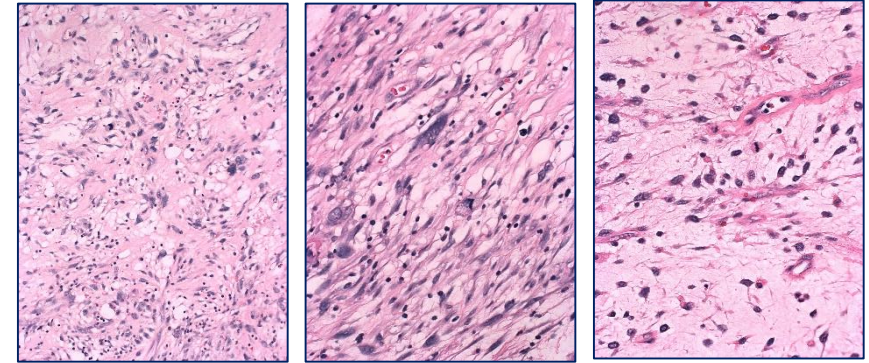
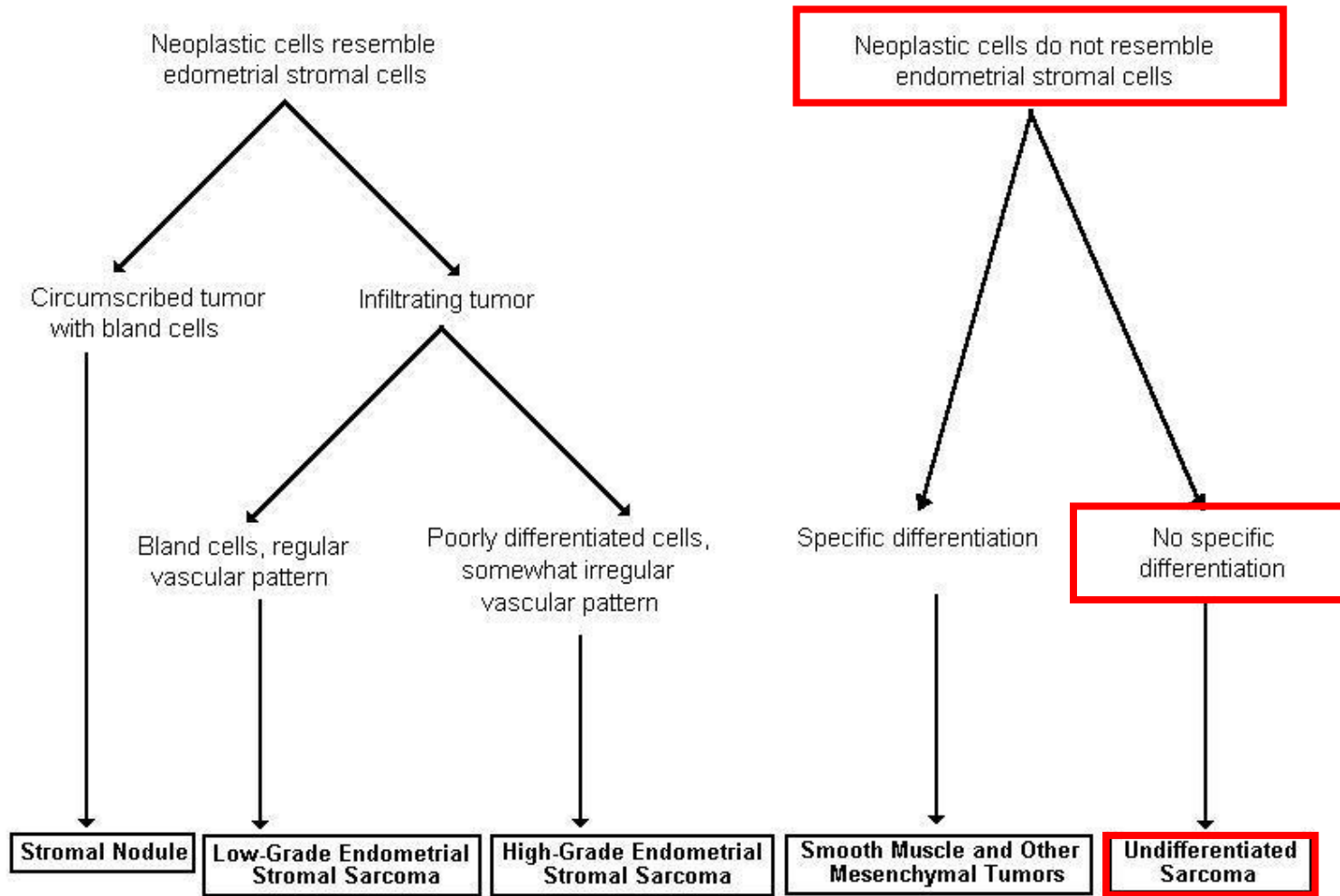
FIGO 2009 staging of uterine sarcoma

(1) Leiomyosarcomas and endometrial stromal sarcomas (ESS)*

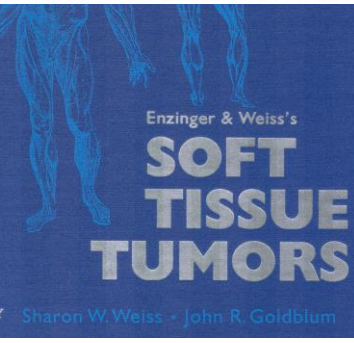
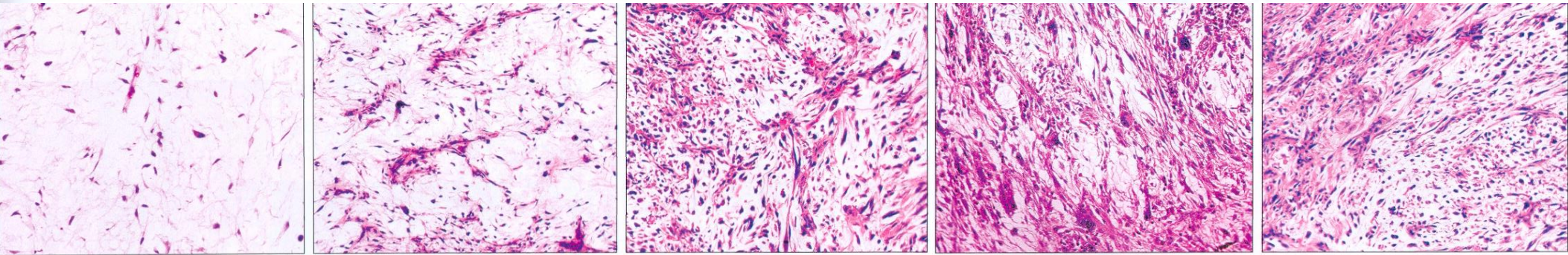
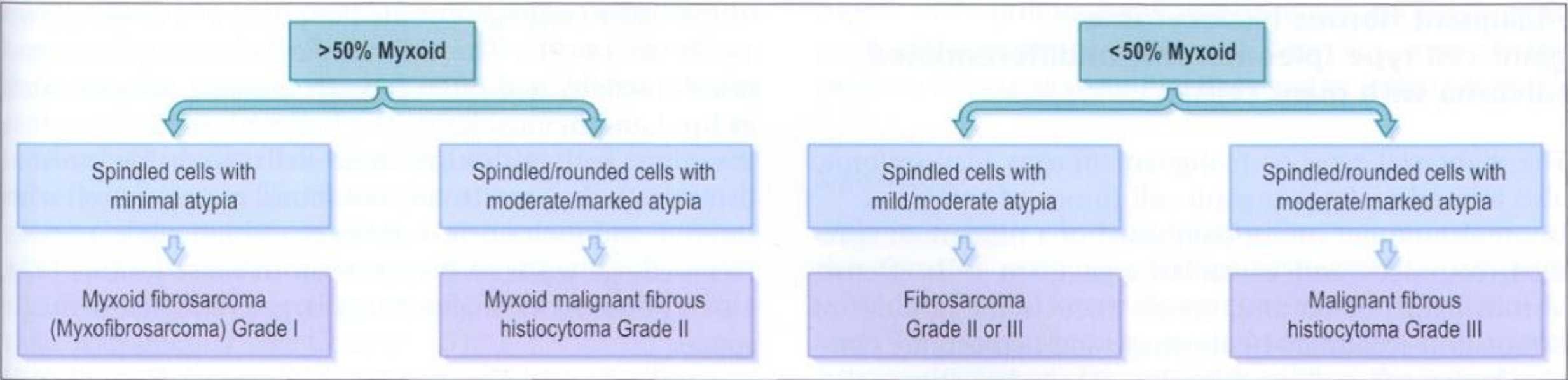
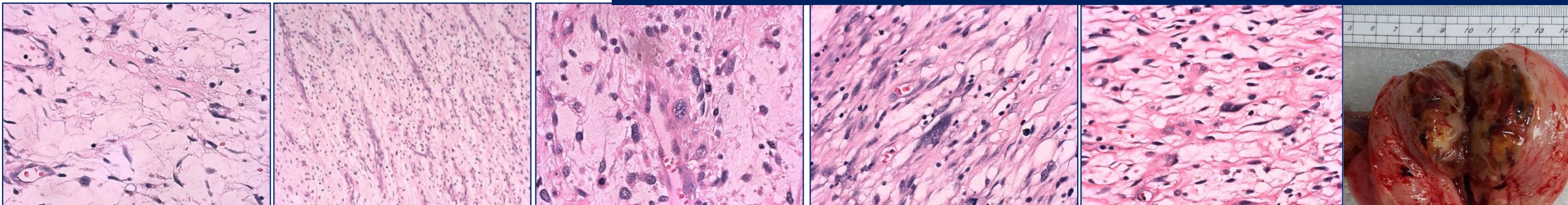
Stage	Definition
I	Tumor limited to uterus
IA	≤ 5 cm
IB	> 5 cm
II	Tumor extends beyond the uterus, within the pelvis
IIA	Adnexal involvement
IIB	Involvement of other pelvic tissues
III	Tumor invades abdominal tissues (not just protruding into the abdomen).
IIIA	One site
IIIB	> one site
IIIC	Metastasis to pelvic and/or para-aortic lymph nodes
IV	Tumor invades bladder and/or rectum
IVA	Tumor invades bladder and/or rectum
IVB	Distant metastasis

*Note:
Simultaneous endometrial stromal sarcomas of the uterine corpus and ovary/pelvis in association with ovarian/pelvic endometriosis should be classified as independent primary tumors.

...základný algoritmus mezenchýmových nádorov maternice



- **VIM+/CDK4+/CD10±/ER±**
- **↑ Ki67 index**
- **negat. svalové, epitelové, melanómové markery**
- **negatívna genetika na myxoidný LS**



Cytologic Features of a Primary Myxoid Malignant Fibrous Histiocytoma Arising in the Uterus

A Case Report

Yasuhiko Kiyozuka, M.D., Ph.D., Kohji Tsuta, M.D., Takako Akamatsu, C.M.I.A.C., Tomohiko Matsuyama, C.T., Hirohisa Mizuta, M.D., Koji Nakanishi, M.D., Shiro Nakano, M.D., Ph.D., and Airo Tsubura, M.D., Ph.D.

BACKGROUND: Primary malignant fibrous histiocytoma (MFH) of the uterus is extremely rare. The 10 cases reported in the literature all involved the pleomorphic variant, and to the best of our knowledge, the myxoid variant has not been reported before. We describe the cytologic findings of primary uterine myxoid MFH in relation to the myxoid component, potentially leading to an incorrect diagnosis.

CASE: A 68-year-old woman presented with a primary uterine tumor. Endometrial cytology showed numerous loosely arranged, spindle-shaped fibroblastlike cells; atypical histiocytelike cells;

and giant cells with a necrotic background. The overall cytologic picture was of a degenerated pleomorphic leiomyosarcoma with an inconclusive diagnosis. A diagnosis of myxoid MFH was established after electron microscopic and immunohistochemical studies of the primary tumor and tumor transplanted, as primary cultured cells, in nude mice. The patient underwent an exploratory laparotomy and died of tumor progression 38 days after the initial consultation, without treatment.

CONCLUSION: Because of overlapping cytologic features among uterine sarcomas with myxoid stroma, it is

An accurate cytologic diagnosis of myxoid MFH...may be achieved by seeking isolated, atypical, spindle, multinucleated, undifferentiated, small, round cells with vacuolated cytoplasm....

From the Department of Pathology II, Kansai Medical University, Moriguchi, Osaka, and Department of Cytopathology, Nara National Hospital, and Department of Obstetrics and Gynecology, Saiseikai Nara Hospital, Nara, Japan.

Dr. Kiyozuka is Assistant Professor, Department of Pathology II, Kansai Medical University.

Dr. Tsuta is Graduate Student, Department of Pathology II, Kansai Medical University.

Ms. Akamatsu is Cytotechnologist, Department of Pathology II, Kansai Medical University.

Mr. Matsuyama is Cytotechnologist, Department of Cytopathology, Nara National Hospital.

Drs. Mizuta, Nakanishi and Nakano are Gynecologists, Department of Obstetrics and Gynecology, Saiseikai Nara Hospital.

Dr. Tsubura is Professor, Department of Pathology II, Kansai Medical University.

Address reprint requests to: Yasuhiko Kiyozuka M.D., Ph.D., Department of Pathology II, Kansai Medical University, 10-15 Fumizono, Moriguchi, Osaka 570-8506, Japan (kiyozuka@takii.kmu.ac.jp).

Financial Disclosure: The authors have no connection to any companies or products mentioned in this article.

Received for publication June 26, 2000.

Accepted for publication December 27, 2000.

[In Vivo](#). 2001 May-Jun;15(3):227-31.

Myxoid malignant fibrous histiocytoma of the uterus: a case with immunohistochemical, ultrastructural and tumor cell culture studies.

[Kiyozuka Y](#)¹, [Mizuta H](#), [Nakanishi K](#), [Nakano S](#), [Tsubura A](#).


[Cancer Genet Cytogenet](#). 2001 May;127(1):7-15.

Novel cell lines established from a human myxoid malignant fibrous histiocytoma arising in the uterus.

[Kiyozuka Y](#)¹, [Nakagawa H](#), [Uemura Y](#), [Senzaki H](#), [Yamamoto A](#), [Noguchi T](#), [Mizuta H](#), [Nakanishi K](#), [Nakano S](#), [Tsubura A](#).

Epidemiologická faktografia...

- incidencia Sa maternice je **1.5-1.7 / 100000 žien**
- **ESS sú druhou najčastejšou mezenchýmovou neoplazmou maternice**
- ESS predstavujú cca **1% všetkých malignít maternice / cca 7-25% malígnych mezenchýmových nádorov maternice**



... a WHO klasifikácia ESS, 2014

- **ESN** – endometriálny stromálny nodul
- **LGESS** – low-grade ESS
- **HGESS** – high-grade ESS
- **UUS** – nediferencovaný sarkóm maternice

Pathology (February 2018) 50(2), pp. 162–177

GYNAECOLOGICAL PATHOLOGY

Endometrial stromal sarcomas and related neoplasms: new developments and diagnostic considerations

LIEN HOANG¹, SARAH CHIANG² AND CHENG-HAN LEE³

¹Department of Anatomical Pathology, Vancouver General Hospital, Vancouver, BC, Canada; ²Department of Pathology, Memorial Sloan Kettering Cancer Center, New York, NY, United States; and ³Department of Pathology, BC Cancer Agency, Vancouver, BC, Canada



- Endometrial stromal sarcoma can be defined into low and high grade categories and this separation is clinically relevant
 - By morphology, immunophenotype, genetics
- Undifferentiated uterine sarcoma is a diagnosis of exclusion (if uniform, consider high grade ESS)

Nediferencovaný sarkóm maternice - UUS

tumor vznikajúci v endometriu alebo myometriu, ktorý

- **neprispeje k endometriálnej stróme** (bez morfológických známkov endometriálnej strómy v proliferatívnej fáze)
- má **HG cytologické črty** (nukleárny pleomorfizmus a anaplázia)
- **nemá špecifickú diferenciáciu**
- vykazuje **IHC „overlap“**
- má často **mutácie p53**
- komplexné chromozómové alterácie
- má veľmi zlú prognózu

- **Klinika: PM ženy (priem.vek 60r.)** s krvácaním, bolesťou v panve
- **Makro:** polypoid./intraluminál., >10cm, časté ložiská krvácania a nekrózy
- **Mikro:** pleomorfný/monomorfný vzhľad, skôr deštruktívny rast, vretenovité alebo epitelooidné bunky, vysoký st. celulárnej atypie, vysoká MA, „herringbone/storiform“ alebo difúzny rast, myxoidné zmeny, LVI, môže byť heterológna diferenciácia



Nediferencovaný sarkóm maternice - UUS

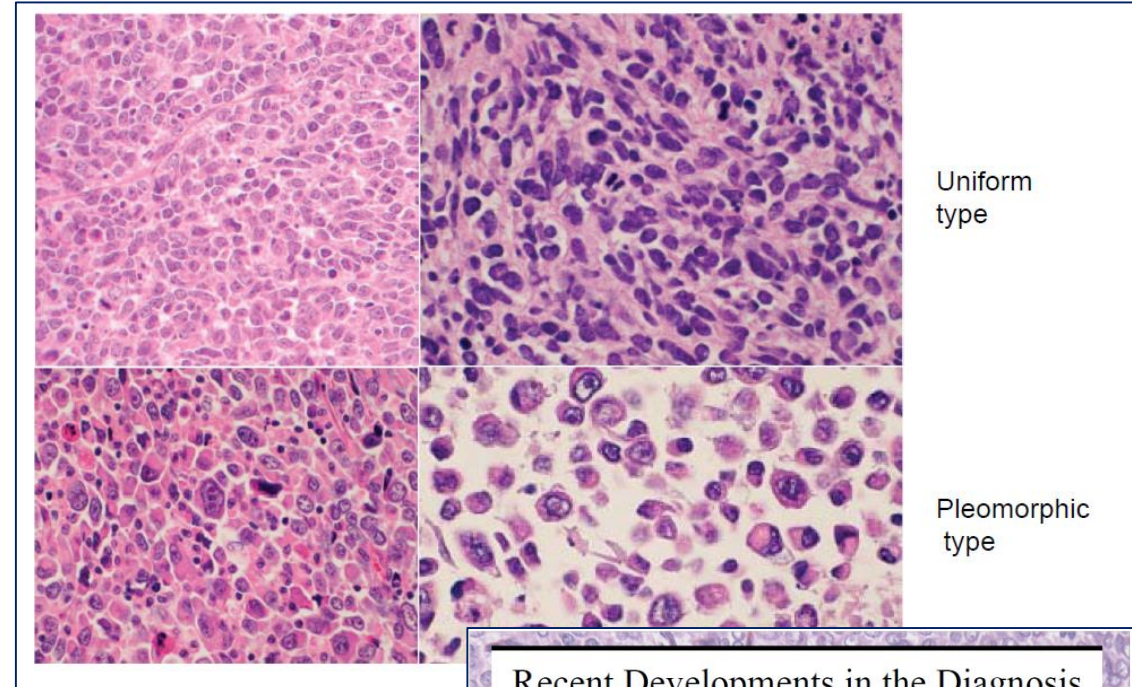
Kurihara et al. (2008) rozdelili UES na:

- UES s nukleárnou uniformitou **(UES-U)**
- UES s nukleárnou pleomorfiou **(UES-P)**

] S. Kurihara, Y. Oda, Y. Ohishi Y, Iwasa A, Takahira T, Kaneki E, et al. Endometrial stromal sarcomas and related high-grade sarcomas: Immunohistochemical and molecular genetic study of 31 cases. Am. J. Surg. Pathol. 2008;32(8):1228–38.

Genetický profil UUS:

- Komplexné chromozómové zmeny
- Zisky 2q; 4q; 6q; 7p; 9q; 20q a straty 3q; 10p; 14q



Recent Developments in the Diagnosis of Uterine Sarcomas

Marisa R. Nucci, M.D.

Associate Professor of Pathology

Division of Women's and Perinatal Pathology

Department of Pathology

Brigham and Women's Hospital

Boston, MA



UCSF Current Issues in Anatomic Pathology 2014



Onkologický ústav sv. Alžbety, s.r.o.
812 50 Bratislava, Heydukova 10



Vývoj poznatkov a klasifikácií ESS

February 2018) 50(2), pp. 162–177

GYNAECOLOGICAL PATHOLOGY

Endometrial stromal sarcomas and related neoplasms: new developments and diagnostic considerations

LIEN HOANG¹, SARAH CHIANG² AND CHENG-HAN LEE³

¹Department of Anatomical Pathology, Vancouver General Hospital, Vancouver, BC, Canada; ²Department of Pathology, Memorial Sloan Kettering Cancer Center, New York, NY, United States; and ³Department of Pathology, BC Cancer Agency, Vancouver, BC, Canada



The clinicopathologic features of *YWHAE-FAM22* endometrial stromal sarcomas – a histologically high-grade and clinically aggressive tumor

Am J Surg Pathol 2012; 36:641-53

<p>Mesenchymal Sarcoma</p> <ul style="list-style-type: none"> a. Pure homologous <ul style="list-style-type: none"> i. Endometrial stromal sarcoma ii. Stromatosis endometriosis b. Pure heterologous c. Mixed homologous d. Mixed heterologous <p>Unclassified Sarcoma</p>	<p>1959 Ober</p>	<p>Norris & Taylor, n=53 Separated stromal neoplasms by mitotic activity (cut off: 10/10 HPF)</p>
<p>Evans, n=18 Found mitotic activity was not a reliable prognosticator; Emphasized histologic appearance of sarcoma</p>	<p>1981</p>	<p>1970 Kempson & Bari</p> <ul style="list-style-type: none"> Pure Sarcoma <ul style="list-style-type: none"> a. Stromal sarcoma b. Endolymphatic stromal myosis Mixed Sarcoma Malignant mixed Müllerian tumor
<p>Endometrial stromal nodule</p> <p>Low-grade endometrial stromal sarcoma</p> <p>High-grade endometrial stromal sarcoma</p> <p>Undifferentiated sarcoma</p>	<p>1992 AFIP</p>	<p>Chang <i>et al.</i>, n=117 Found mitotic activity was not a prognosticator across all stages of endometrial sarcoma</p> <p>1990</p> <p>Sreekanthiah <i>et al.</i>, n=1 First described t(7;17) in low-grade ESS</p> <p>1991</p> <p>1994</p> <p>WHO 2nd Ed.</p> <ul style="list-style-type: none"> Endometrial stromal nodule Low-grade endometrial stromal sarcoma High-grade endometrial stromal sarcoma
<p>Koontz <i>et al.</i>, n=1 Identified <i>JAZF1</i> and <i>SUZ12</i> genes involved in LG-ESS fusions</p> <p>Leunen <i>et al.</i>, n=1 First described t(10;17)(q22;p13) in ESS</p> <p>Kurihara <i>et al.</i>, n=12 Separated UES into UES-P and UES-U</p>	<p>2001</p> <p>2003</p> <p>2008</p>	<p>Removal of high-grade category</p> <p>2003</p> <p>WHO 3rd Ed.</p> <ul style="list-style-type: none"> Endometrial stromal nodule Low-grade endometrial stromal sarcoma Undifferentiated endometrial sarcoma
<p>Lee <i>et al.</i>, n=12 Documented t(10;17) <i>YWHAE-NUTM2A/B</i> in HG-ESS</p>	<p>2013</p>	<p>Reintroduction of high-grade category</p> <p>2014</p> <p>WHO 4th Ed.</p> <ul style="list-style-type: none"> Endometrial stromal nodule Low-grade endometrial stromal sarcoma High-grade endometrial stromal sarcoma Undifferentiated uterine sarcoma

„znovuzrodenie“ HG ESS


- Táto skupina sa vyčlenila z UES s uniformnými jadrovými črtami a s dôkazom t(10;17)(q22;p13)

The clinicopathologic features of *YWHAE-FAM22* endometrial stromal sarcomas – a histologically high-grade and clinically aggressive tumor

Am J Surg Pathol 2012; 36:641-53

YWHAE-FAM22 (NUTM2)

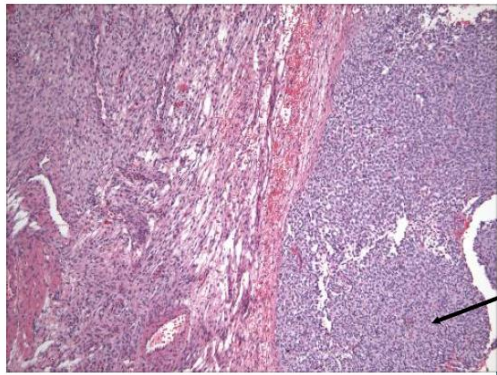
- vzniká v maternici
- makroskopická masa s inváziou do myometria (1-12cm)
- môže sa propagovať extrauterínne
- jazykovitý typ invázie do myometria
- vaskulárna invázia
- vetviaca sieť kapilár v stróme
- **dve bunkové populácie (HG okruhlobunková (ER/PR/CD10-) a LG vretenobunkový komponent (ER/PR/CD10+))**

- 
- sú rýchlejšie progredujúce v porovnaní s ESS s rearranged JAZF1
 - vykazujú vyšší grade (NIE PLEOMORFNÝ) v porovnaní s ESS s rearranged JAZF1

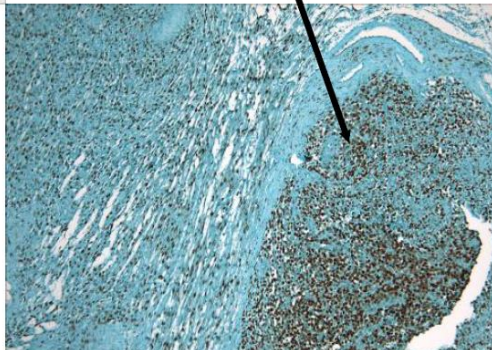


Cyclin D1 as a diagnostic immunomarker for endometrial stromal sarcoma with *YWHAE-FAM22* rearrangement

Am J Surg Pathol, 2012; 36: 1562-70



Cyclin D1 positive (> 75%) in histologically high grade component



Tumor type	Number of cases studied	Cyclin D1 positive cases
ESS with <i>YWHAE-FAM22</i> rearrangement	12	12 (100%)
ESS with <i>JAZF1/SUZ12/PHF1/EPC1</i> rearrangement	34	0 (0%)
ESS with no demonstrable rearrangement	21	0 (0%)
UES - with nuclear pleomorphism (UES-P)	13	0 (0%)
UES - with nuclear uniformity (UES-U)	8	2 (25%)
Uterine leiomyosarcoma *	119	1 (1%)
Adenosarcoma †	25	0 (0%)
Carcinosarcoma	13	0 (0%)
PEComa	4	0 (0%)
Leiomyoma	49	0 (0%)
Polypoid endometriosis	7	0 (0%)
Endometrial stromal nodule	3	0 (0%)
Uterine tumors resembling ovarian sex cord tumor	2	0 (0%)

* 80 primary and 39 metastatic tumors

† 8 of 25 adenosarcomas show sarcomatous overgrowth.

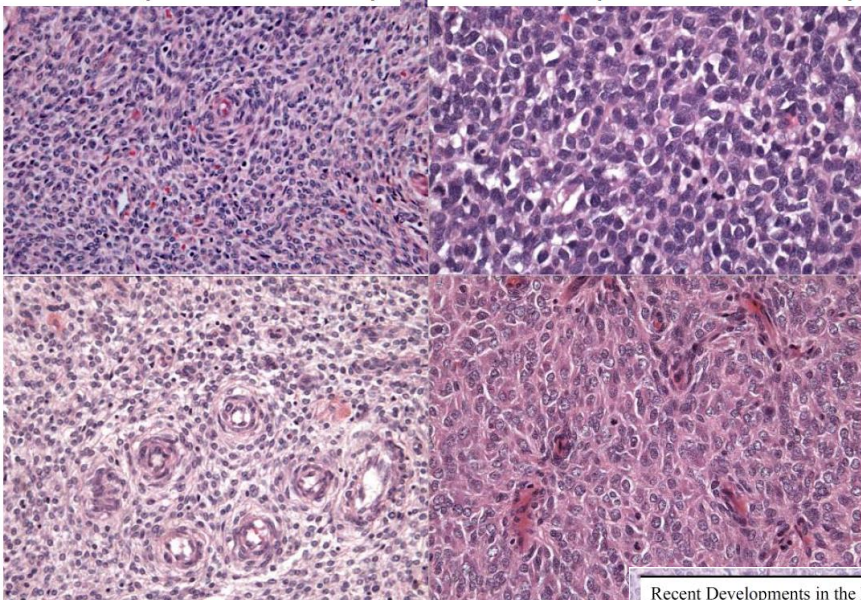


The clinicopathologic features of *YWHAE-FAM22* endometrial stromal sarcomas – a histologically high-grade and clinically aggressive tumor

Am J Surg Pathol 2012; 36:641-53

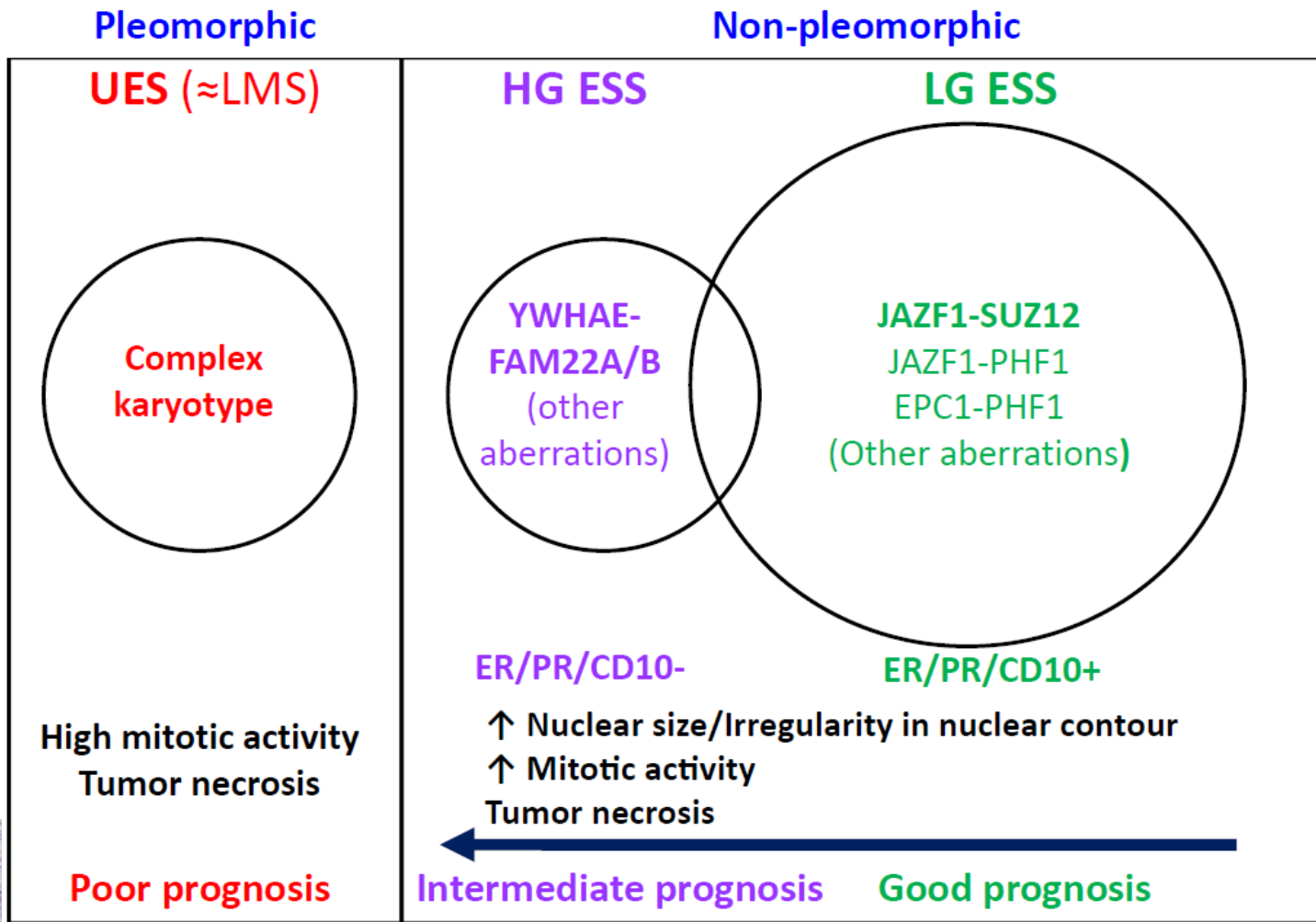
LG-ESS (JAZF1-SUZ12)

HG-ESS (YWHAE-FAM22)



Recent Developments in the Diagnosis of Uterine Sarcomas
 Marisa R. Nucci, M.D.
 Associate Professor of Pathology
 Division of Women's and Perinatal Pathology
 Department of Pathology
 Brigham and Women's Hospital
 Boston, MA
 UCSF Current Issues in Anatomic Pathology 2014

Proposed classification of uterine sarcoma



Genetické alterácie ESS

LG-ESS

t(7;17)(p15;q21) → the fusion of JAZF1 and SUZ12(JJAZ1) genes at 7p15 and 17q21, respectively

t(6;7)(p21;p15) → the JAZF1–PHF1 fusion gene at 7p15 and 6p21, respectively

t(6;10)(p21;p11) → the PHF1–EPC1 fusion gene at 6p21 and 10p11, respectively

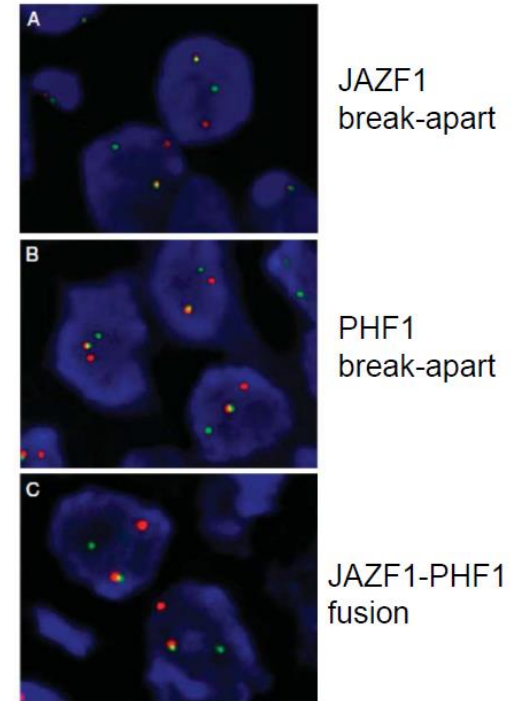
t(1;6)(p34;p21) → the PHF1–MEAF6 fusion gene at 6p21 and 1p34, respectively

t(X;22)(p11;q13) → the ZC3H7B–BCOR fusion gene at Xp11 and 22q13, respectively

t(X ;17) (p11.2;q21.33) → the MBTD1-CXorf67 fusion gene at Xp11.2 and 17q21.33, respectively

HG-ESS

t(10;17)(q22;p13) → the YWHAE-FAM22 (NUTM2AB) fusion gene at 10q22 and 17 p13, respectively



ESS = endometrial stromal sarcoma; HG-ESS = high-grade endometrial stromal sarcoma; LG-ESS = low-grade endometrial stromal sarcoma.

... na scéne sa objavil nový podtyp HG ESS

Am J Surg Pathol. 2017 January ; 41(1): 12–24. doi:10.1097/PAS.0000000000000721.

Novel High-Grade Endometrial Stromal Sarcoma: A Morphologic Mimicker of Myxoid Leiomyosarcoma

Lien N. Hoang¹, Amandeep Aneja¹, Niamh Conlon², Deborah F. Delair¹, Sumit Middha¹, Ryma Benayed¹, Martee L. Hensley³, Kay J. Park¹, Travis J. Hollmann¹, Meera R. Hameed¹, Cristina R. Antonescu¹, Robert A. Soslow^{1,*}, and Sarah Chiang^{1,*}

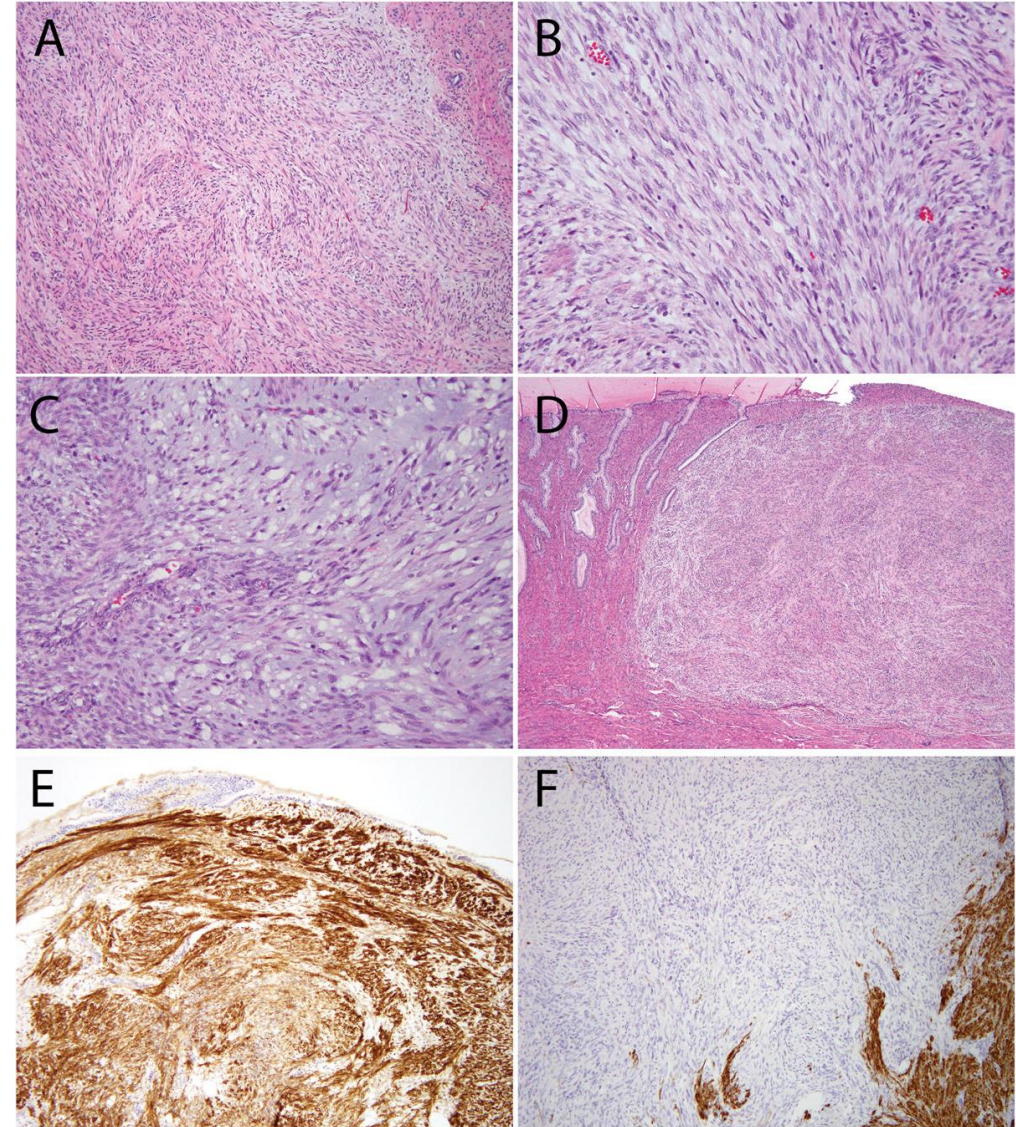
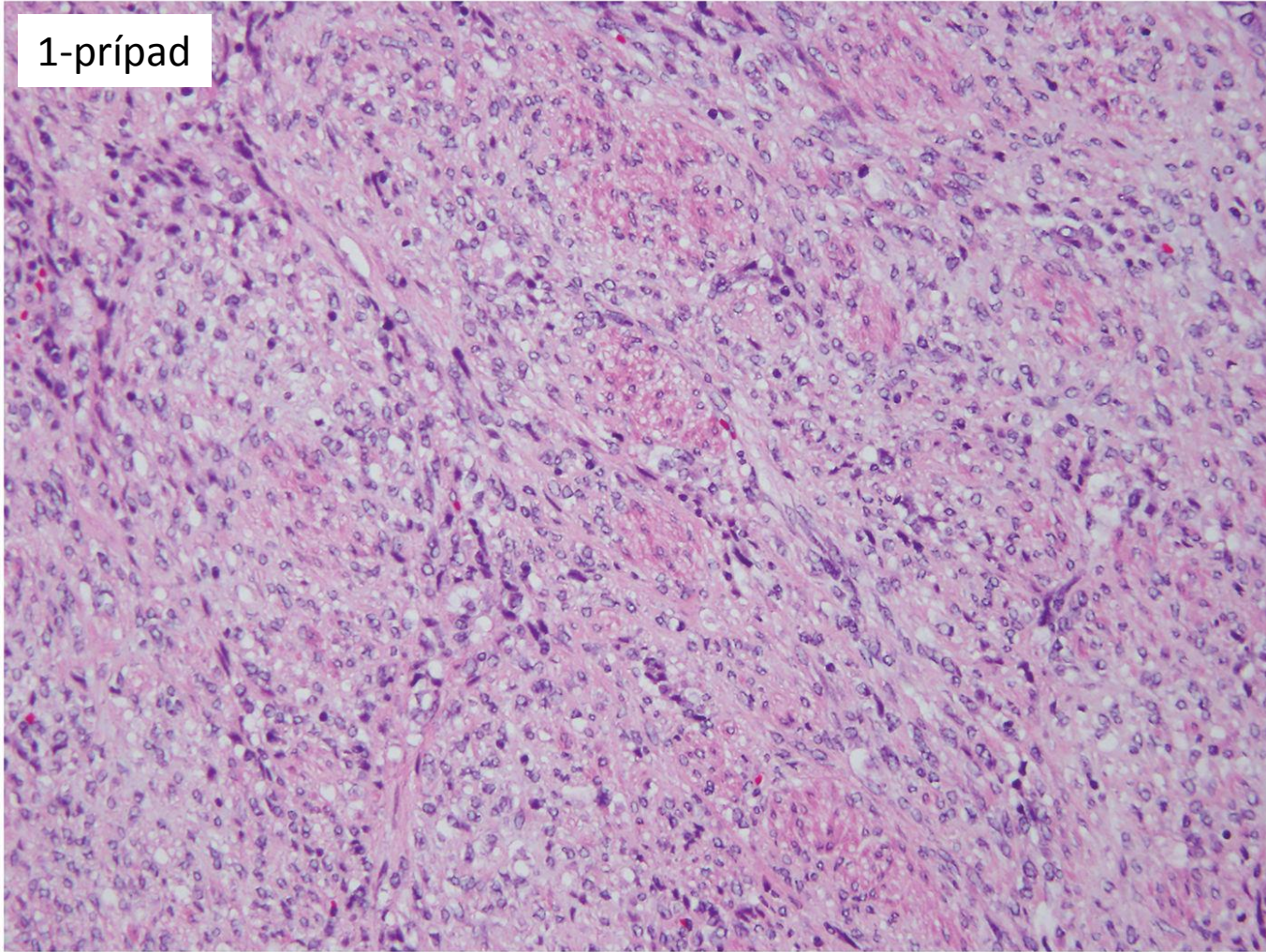
¹Department of Pathology, Memorial Sloan Kettering Cancer Center, New York, NY, USA

²Department of Pathology, Cork University Hospital, Wilton, Cork, Ireland ³Gynecologic Medical Oncology Service, Department of Medicine, Memorial Sloan Kettering Cancer Center, Weill Cornell Medical College, New York, NY, USA

- 3 prípady **ESS s HG morfológiou (extenzívne myxoidné črty)** a agresívnym správaním
- **morfológia prekrývajúca sa s myxoid. leiomyosarkómom maternice** (dig.dg. IHC?!)
- jedinečná genetická alterácia – **fúzia génov ZC3H7B-BCOR t(X;22)(p11.4;q13.2)** – potvrdená sekvenáciou a FISH
- 1x opísaná Panagopoulos et al. (2013) – 2 prípady (CD10+/ ER+/- PR+/-)
- dif.dg. s naším prípadom – **difúzna silná expresia CD10 vo všetkých 3 prípadoch**
- BCOR znovusporiadanie aj v osifikujúcom fibromyxoidnom tumore, nediferencovaných malobunkových tu, nediferencovaných vretenobunkových sa, CCSa obličiek, a pod.
- **BCOR** – BCL-6 interagujúci korepresor – potencuje funkciu BCL-6

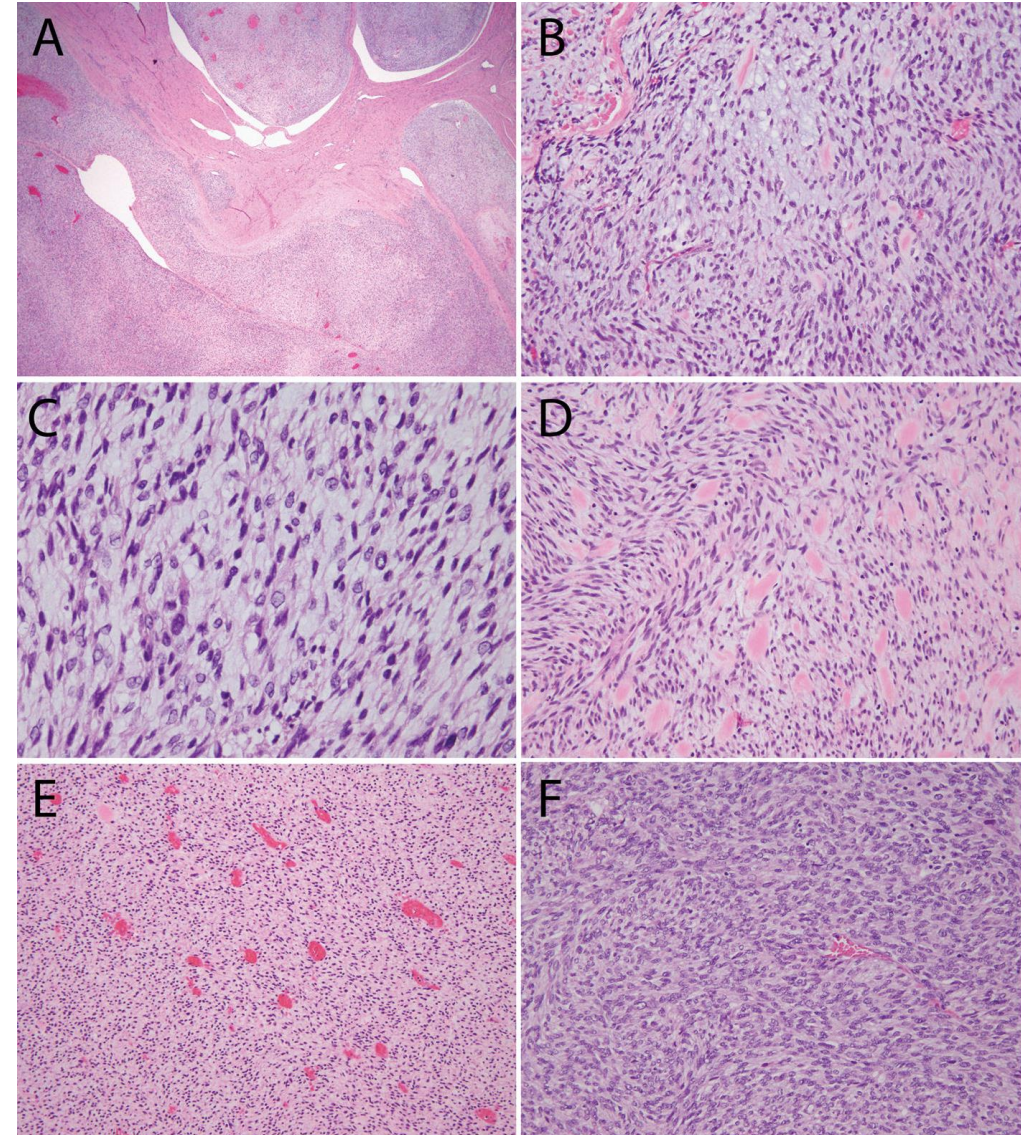
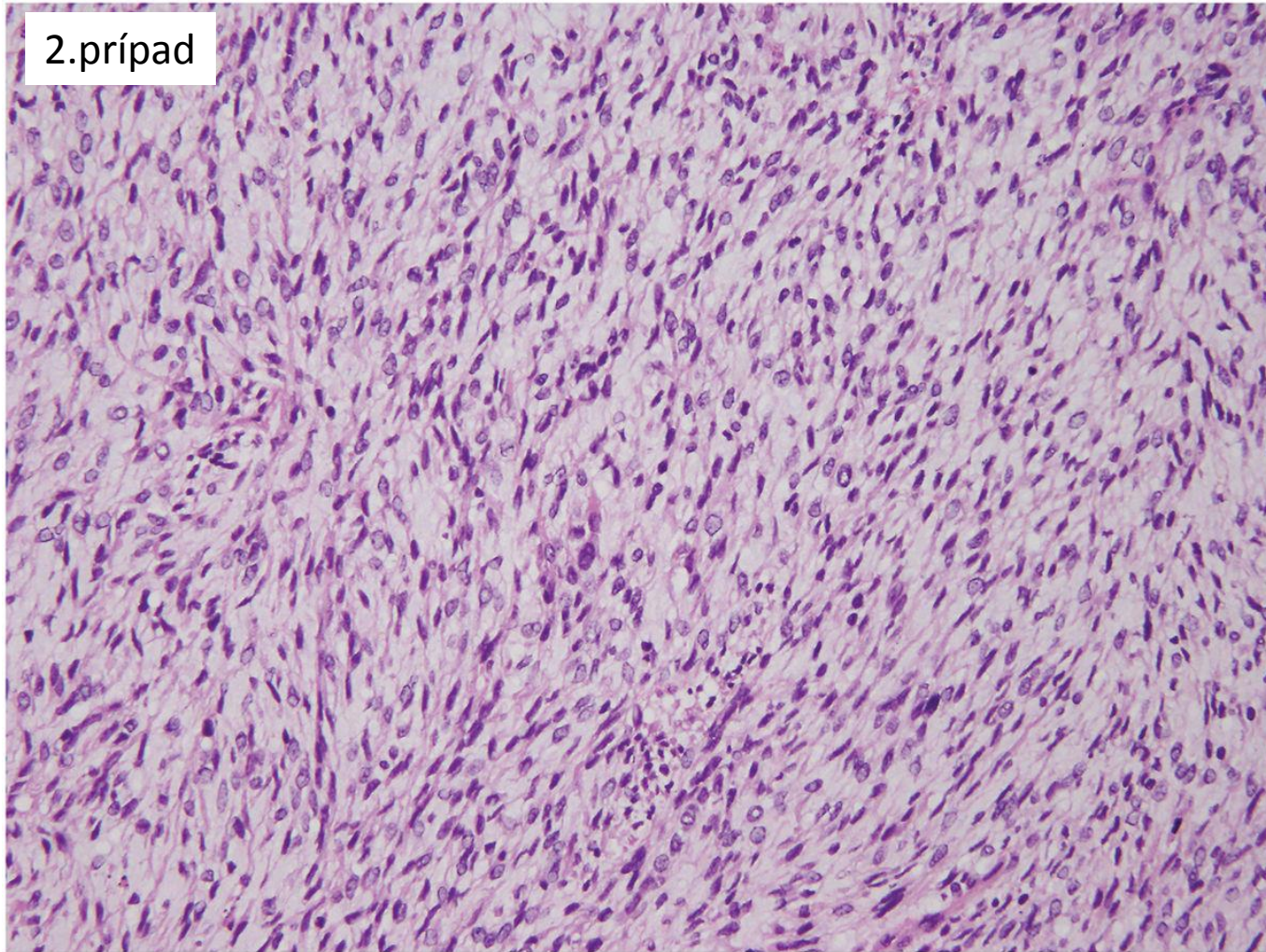
Morfológia aj IHC odlišné od nášho prípadu

1-prípád



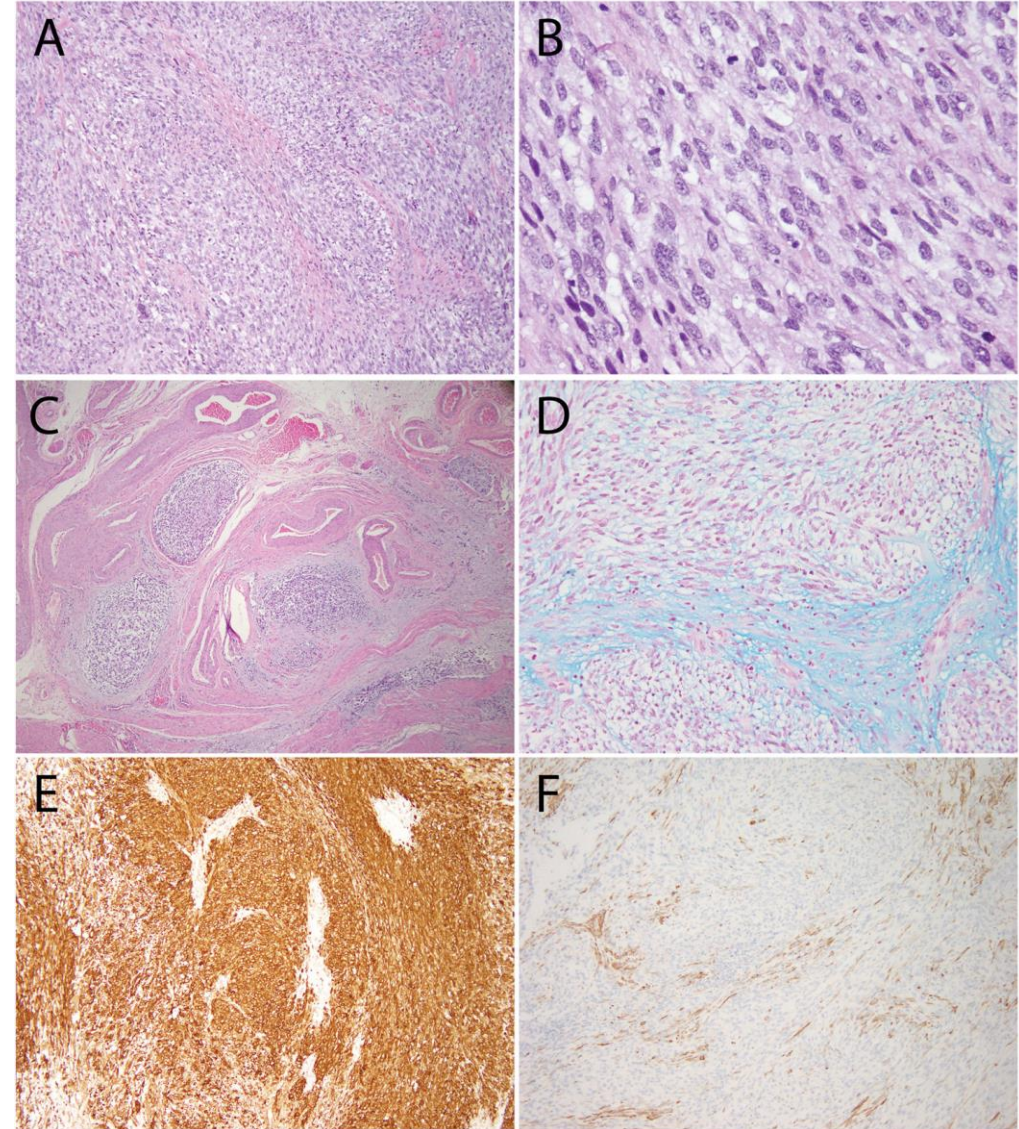
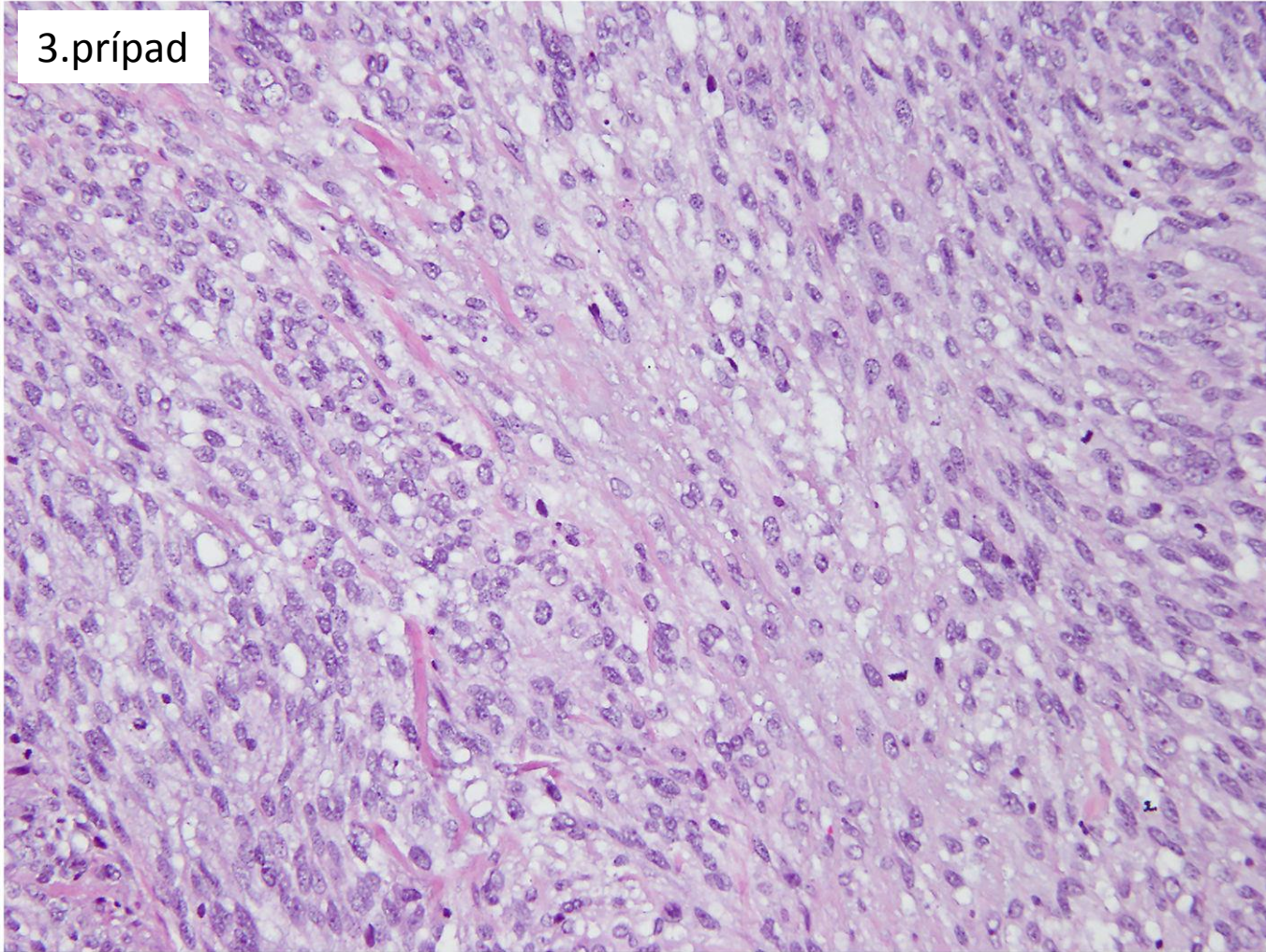
Morfológia aj IHC odlišné od nášho prípadu

2.případ



Morfológia aj IHC odlišné od nášho prípadu

3.prípád



dif. dg. ESS

Table 1 Differential diagnosis of endometrial stromal neoplasms

ESN	LGESS	HGESS (YWHAЕ rearranged)	ESS (BCOR rearranged)	UUS
Cellular leiomyoma Endometrial polyp with cellular stroma (curettage) LGESS LGESS with limited infiltration UTROSCT	ESN ESN with limited infiltration Adenomyosis with sparse glands Intravascular menstrual endometrium IVL LMS HGESS UTROSCT PEComa GIST HPC/SFT	LGESS ESS (BCOR) UUS LMS PEComa GIST PNET/Ewing's Synovial sarcoma	Myxoid LMS IMFT HGESS (YWHAЕ) LGESS with fibromyxoid changes UUS	LGESS HGESS (YWHAЕ) ESS (BCOR) LMS Adenosarcoma Carcinosarcoma Lymphoma Melanoma Rhabdomyosarcoma Undifferentiated carcinoma



dif. dg. ESS

- **LG ESS** – jasná morfológia, problémom by mohol byť fibromyxoidný variant
- **HG ESS t(10;17) YWHAE-NUTM2A/B** – duálna bunková populácia
- **HG ESS ZC3H7B-BCOR** – relatívne uniformne celulárny usporiadanie vo zväzkoch; bunky vretenovité, v oválnom, vretenovitým alebo okrúhlym jadrom, zriedkavo nukleárny pleomorfizmus; extenzívne myxoidná stroma
- **LMS** – IHC (svalové a hladko-svalové markery)
- **MMMT** – dôkaz epitelovej komponenty
- **Melanóm** – morfológia + IHC
- **ML** – morfológia + IHC
- **RMS** – morfológia + IHC



dif. dg. ESS

IHC	ESN	LGESS	HGESS <i>YWHAE-NUTM2</i>		ESS <i>BCOR</i> ^b	UUS ^c	LM	LMS
			LG	HG				
CD10 ^d	8/8 (100%)	124/174 (73%)	10/12 (83%)	2/27 (7%)	16/16 (100%)	46/76 (61%)	11/44 (25%)	169/307 (55%)
ER ^e	6/6 (100%)	65/78 (83%)	9/11 (82%)	0/23 (0%)	4/12 (33%)	12/52 (23%)	42/45 (93%)	17/62 (27%)
PR ^e	6/6 (100%)	37/44 (84%)	9/11 (82%)	1/26 (38%)	4/10 (40%)	10/63 (16%)	23/25 (92%)	12/41 (29%)
Desmin		52/162 (32%)	0/1 (0%)	0/6 (0%)	1/14 (7%)	12/30 (40%)	41/42 (98%)	210/307 (68%)
Caldesmon		18/121 (15%)		0/2 (0%)	1/10 (10%)	10/30 (33%)	32/35 (91%)	208/299 (70%)
SMA		33/53 (63%)	0/1 (0%)	0/6 (0%)	6/13 (46%)	4/9 (44%)	35/35 (100%)	270/307 (88%)
Cyclin-D1 ^f	0/9 (0%)	0/77 (0%)		28/30 (93%)	7/8 (88%)	17/69 (25%)	0/65 (0%)	1/132 (<1%)
cKIT		0/18 (0%)	3/9 (33%)	13/13 (100%)		1/7 (14%)	0/10 (0%)	0/12 (0%)
DOG1			0/8 (0%)	0/12 (0%)		1/7 (14%)		
β-catenin ^g	2/2 (100%)	11/12 (92%)				6/15 (40%)	0/9 (0%)	
BCOR ^h	0/18 (0%)	0/66 (0%)	0/21 (0%)	21/21 (100%)	13/13 (100%)		0/18 (0%)	0/31 (0%)
Melan-A					0/1 (0%)			
HMB45		2/84 (2%)			0/1 (0%)	2/21 (10%)		15/245 (6%)
ALK1								



dif. dg. ESS – kedy genetika?

- **LG ESS** – pri jasnej morfológii nie je potrebná; pri nejasnostiach, napr. známky hladko-svalovej diferenciácie s vaskulárnou inváziou (dif.dg. vysoko celulárny variant intravenózne leiomatomy), v prípadoch s požiadavkou zachovania fertility
- **HG ESS t(10;17) YWHAE-NUTM2A/B** – v prípadoch, ktoré vykazujú histologické a IHC črty (napr. HG okrúhlymi bunkami s vysokou MA a nekrózami, silná expresia cyclin D1)
- **HG ESS ZC3H7B-BCOR** – obvykle silná expresia CD10/chýbajúca alebo slabá expresia hladko-svalových markerov: uplatnenie genetiky najmä v prípadoch s negatívnou CD10 / SMA + a/alebo h-caldesmon+ v myxoidnom tumore



Case Report

Giant High-Grade Endometrial Stromal Sarcoma Myxoid Variant

Torres-de la Roche LA^{1*}, Vrentas V², Henke RP³, Pozder E⁴, Larbig A⁵, Taperek-Mildner R⁵ and De Wilde RL⁵

¹Clinic for Gynecology, Obstetrics and Gynecological Oncology at Pius Hospital, University Hospital for Gynecology, Carl von Ossietzky University Medical School Oldenburg, Germany

²Clinic for Gynecology, Obstetrics and Gynecological Oncology at Pius Hospital, Oldenburg, Germany.

³Institute of Pathology, Oldenburg, Germany

⁴Clinic for Gynecology and Obstetrics of Carl von Ossietzky University Oldenburg, Germany

⁵Clinic for Gynecology, Obstetrics and Gynecological Oncology at Pius Hospital, Oldenburg, Germany

***Corresponding author:** Torres-de la Roche LA, Clinic for Gynecology, Obstetrics and Gynecological Oncology at Pius Hospital, University Hospital for Gynecology, Carl von Ossietzky University Medical School Oldenburg, Germany

Received: July 24, 2014; **Accepted:** August 26, 2015;

Published: August 28, 2015

Abstract

Introduction: High-grade endometrial stromal sarcoma is characterized by high Cyclin D1 expression and YWHAE-FAM22 genetic fusion. A rare case of myxoid high-grade endometrial stromal sarcoma with fertility-sparing surgery is described, adding to the evidence and better understanding one of the aggressive tumors of the uterine corpus.

Case Presentation: A 36-year old nulliparous woman with desire to have children, rapid abdominal growth, abdominal pain, and suspicion of leiomyoma underwent laparotomy, where a left intraligamentary tumor of 30cm, 8,5 kg size was removed and the posterior uterine wall reconstructed. Histological, immunohistochemical and genetic tests confirmed high grade endometrial stromal sarcoma, myxoid variant, with high cyclin D1 expression and YWHAE t (10;17) (q22;p13.3) rearrangements. Despite counselling, the patient refused complete hysterectomy.

Conclusion: Pre-surgical diagnosis of endometrial sarcomas remains difficult. The use of immunohistochemistry and genetic profile testing permit description of new variants of these tumors, allowing for appropriate counselling and management of patients.

Keywords: Endometrial neoplasms; Sarcoma; Endometrial stromal tumors; Cyclin D1; Oncogene proteins; Fusion YWHAE

↑ Cyclin D1

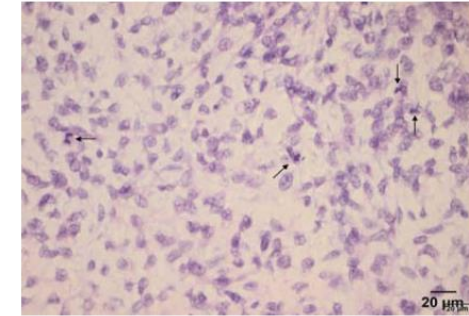


Figure 10: More cellular and frankly atypical area. Four mitotic figures can be seen (arrows). Original magnification x400. Source: Patient's clinical chart.

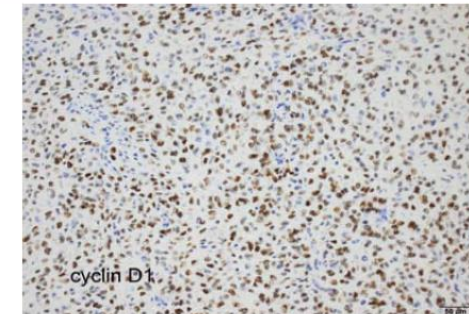


Figure 11: Immunohistochemistry shows strong positivity (brown signals) for Cyclin D1 in the vast majority of tumor cell nuclei. Original magnification x200. Source: Patient's clinical chart.



Myxoid Endometrial Stromal Sarcoma: A Case Report and Literature Review

Young-Mee Lim¹, Gina Nam¹, Heejin Bang², Sewha Kim³, Min-Sun Cho², Seung-Cheol Kim¹ and Yun Hwan Kim^{1*}

¹Department of Obstetrics and Gynecology, Ewha Womans University College of Medicine, Seoul, Korea

²Department of Pathology, Ewha Womans University College of Medicine, Seoul, Korea

³CHA Bundang Medical Center, CHA University, Seongnam, Korea

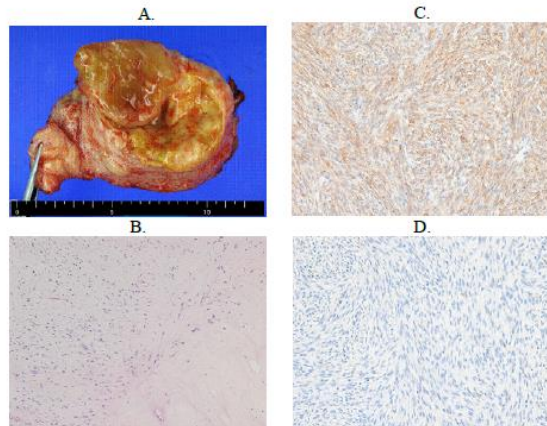


Figure 1: (A) Opened uterus showing an ill-defined bulging out whitish gray to yellow solid mass with central cystic change. (B) Abundant myxoid stroma with low to moderate cellularity (H&E, x100). (C) The tumor is positive for CD10 (x200). (D) The tumor is negative for SM-Actin (x200).

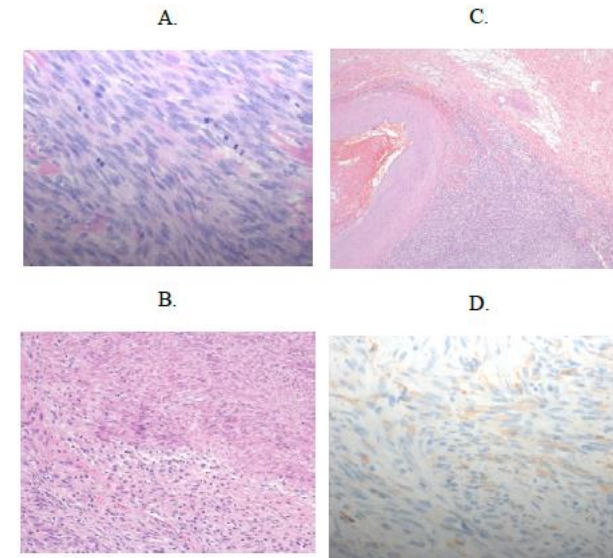


Figure 2: (A) The tumor has high cellularity and high mitotic rate (up to 16/10 HPF) with moderate to marked pleomorphism (H&E, x400). (B) Necrosis in the tumor was observed (H&E, x200). (C) Permeative growth of the tumor was seen (H&E, x40). (D) The tumor is focal positive for Desmin (x400).



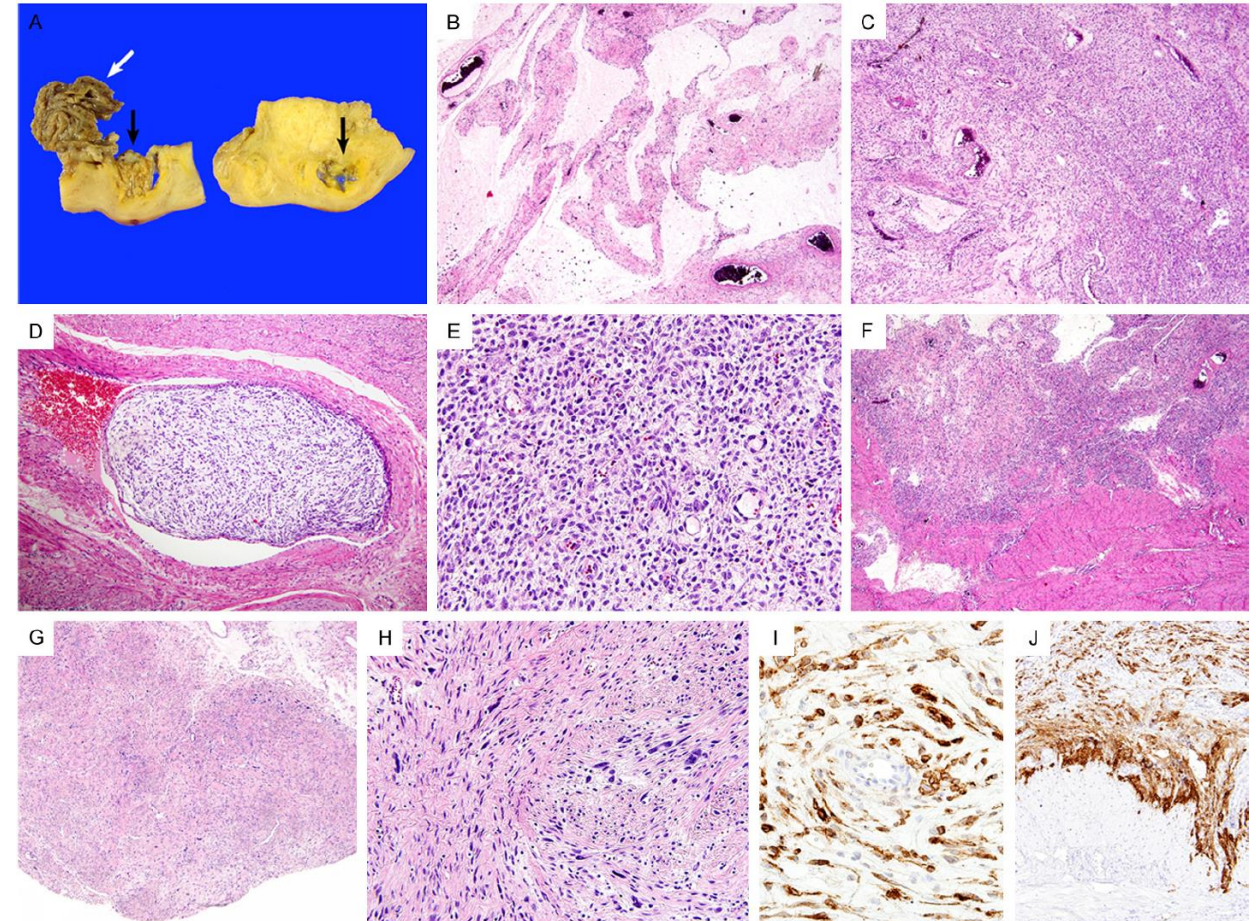
Int J Clin Exp Pathol 2015;8(3):3316-3321
www.ijcep.com /ISSN:1936-2625/IJCEP0005380

Case Report

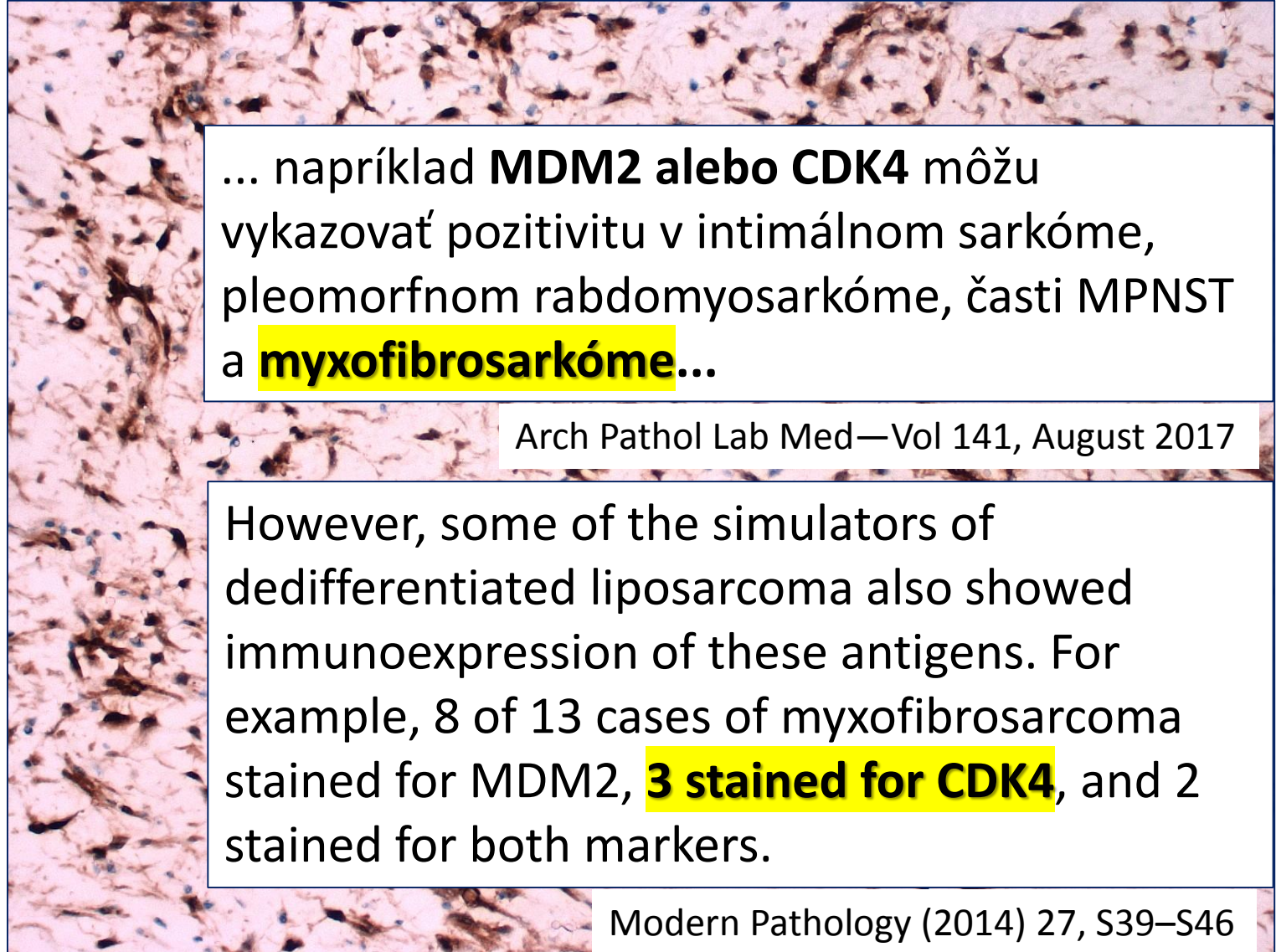
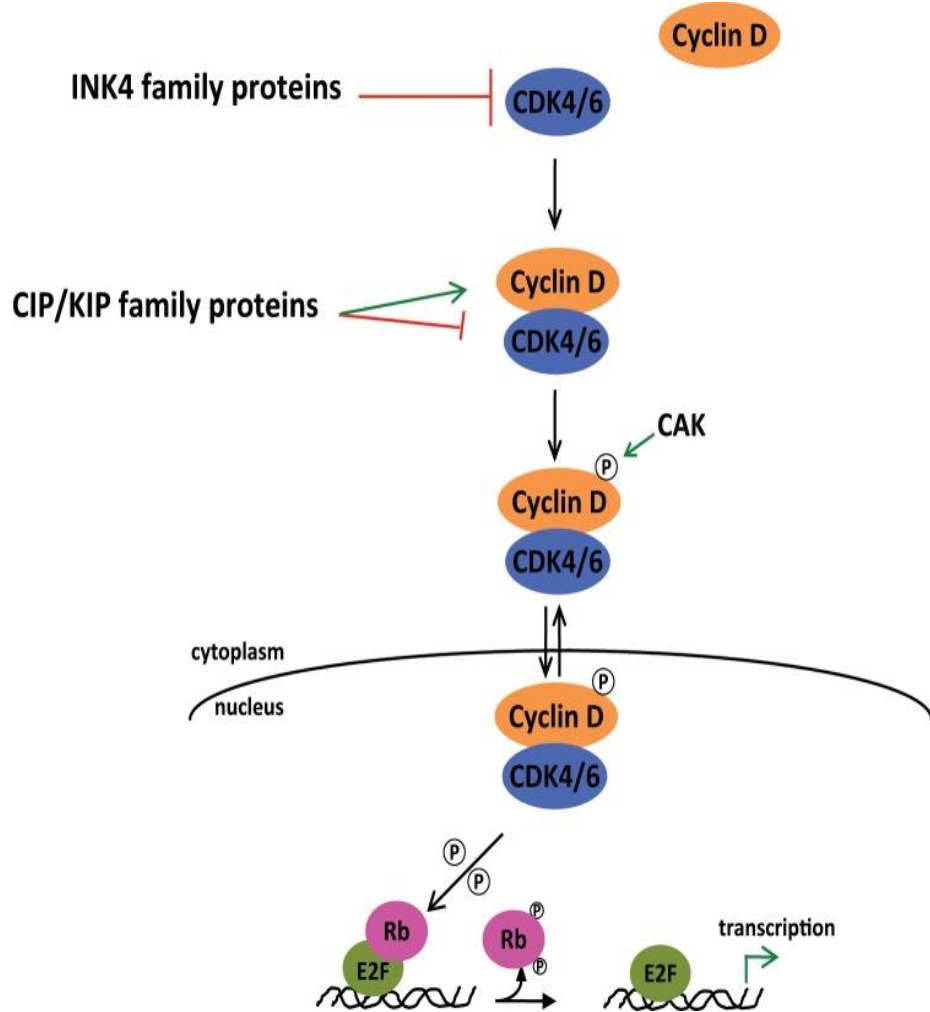
Fibromyxoid variant of endometrial stromal sarcoma with atypical bizarre nuclei

Hyun-Soo Kim^{1*}, Gun Yoon^{2*}, Yoon Yang Jung¹, Yoo-Young Lee³, Sang Yong Song⁴

- silná expresia CD10 / ER / PR
- Ki67 index 1-5% / 5-10%



Ako je to s expresiou CDK4?



Prognóza UUS

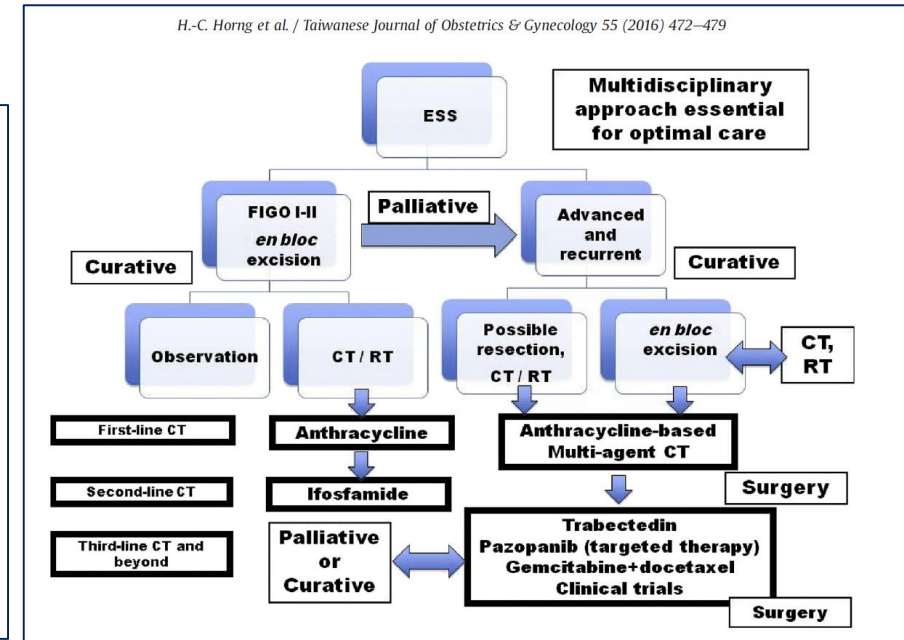
- **všeobecne zlá**
- cca 2/3 pcts je vo vysokom štádiu ochorenia (postihnutie peritonea, pľúc, LU a skeletu)
- významná časť pcts v štádiu I zomiera v priebehu 2 rokov od stanovenia dg.
- 5-ročné prežívanie je 70% (lokalizované ochorenie – št.I), 43% (regionálne ochorenie - št.II-III) a 23% (vzdialené MTS – št.IV)



Ďalší priebeh ochorenia

CT po operácii (16.02.2018)

- **plúca – vľavo S3 solídny nodulus (5mm) susp. z MTS**
- bez známkok lokorecidívy v malej panve, hraničná LU v iliakálnej oblasti vpravo
- „seróm“ v podkoží pod jazvou v dolnej strednej laparotómii



ĽP – tumor (22x20mm) so satelitmi

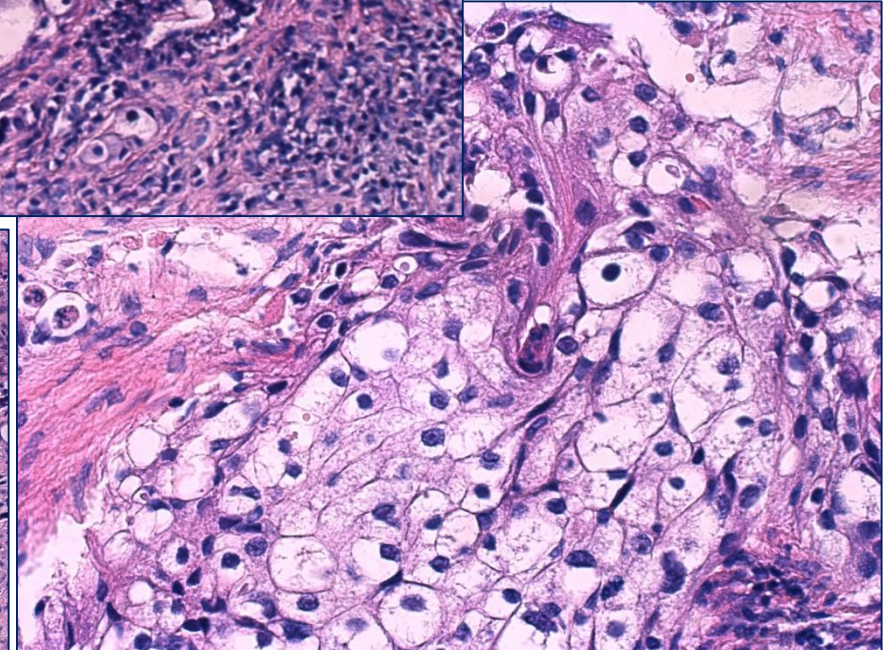
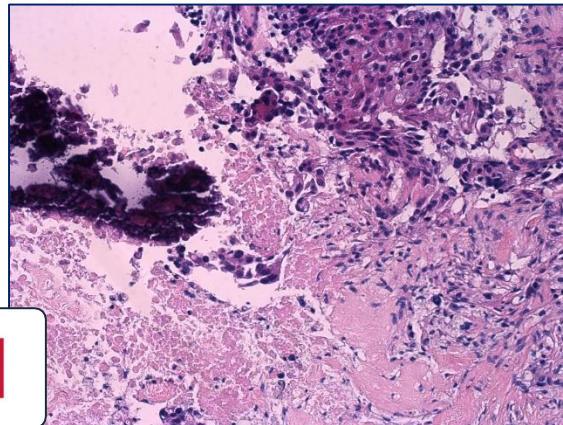
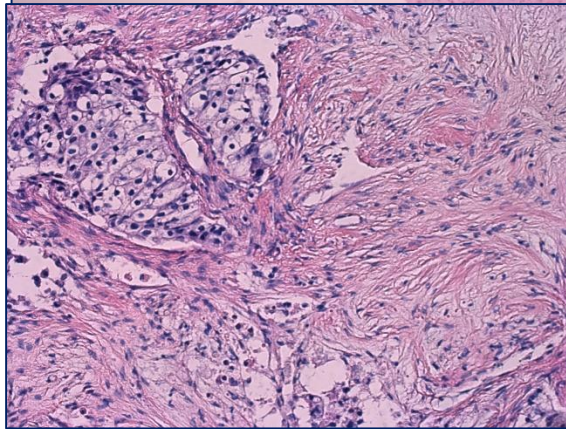
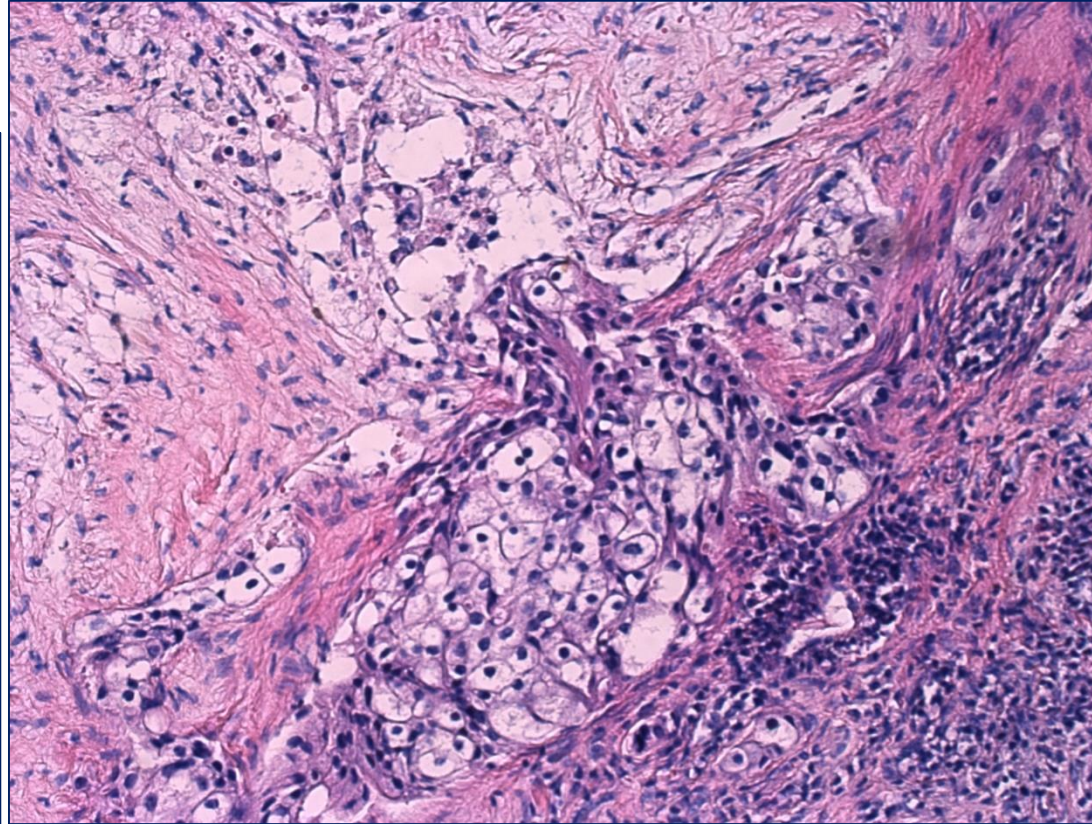
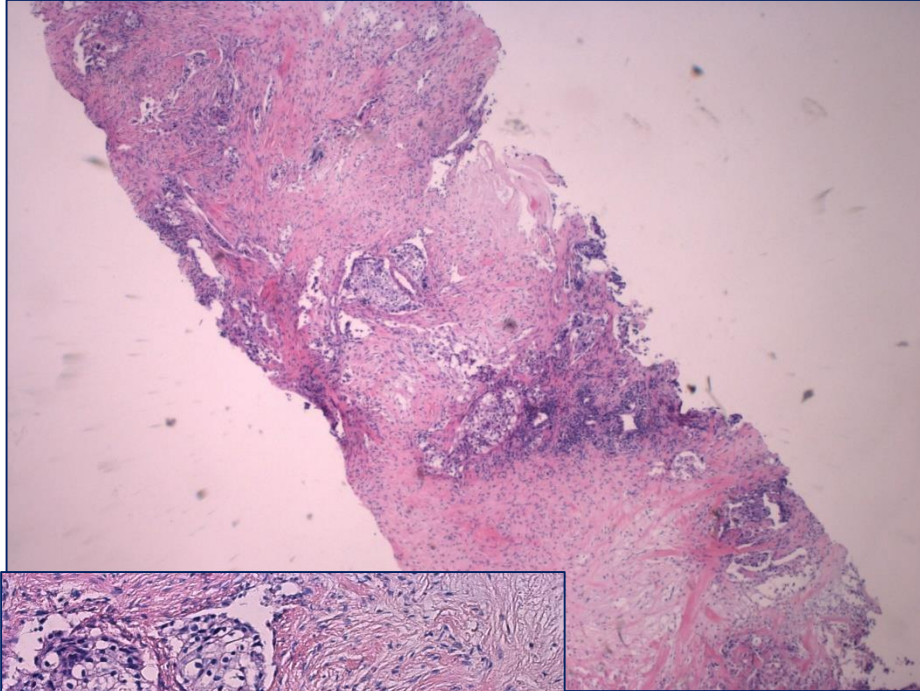
(HLQ/rLQQ a rDQQ) – multifok./ multicentr., retrakcia a zhrubnutie kože

Ľavá axila – LAP (31x19mm) + LU subpektorálne

- ĽP: IDC NST, HG3, ER-/PR-/HER2+; Ki67 50% MUDr.H.Šidlová, Cytopathos, s.r.o. Bratislava
- **neoadi. Th – cvklofosfamid+docetaxel + T / potom oper.**
- pre samotný Sa uteru by nebola nasadená Th




CCB prsníka



záver

- dg. UUS je stanovená **per exclusionem** ostatných dif.dg. jednotiek
- UUS nemá jednoznačný IHC ani genetický profil, najdôležitejší je **starostlivý sampling**



UUS

LGESS

HGESS (YWHAE)

ESS (BCOR)

LMS

Adenosarcoma

Carcinosarcoma

Lymphoma

Melanoma

Rhabdomyosarcoma

Undifferentiated carcinoma